

Cerebral Palsy: MR Findings in 40 Patients

Charles L. Truwit,^{1,2} A. James Barkovich,^{2,3} Thomas K. Koch,³ and Donna M. Ferriero^{3,4}

Purpose: We used MR to retrospectively analyze the brains of patients suffering from cerebral palsy, our aim being to determine MR's role in the assessment of brain damage and the relationship of pre-, peri-, and post-natal events to cerebral palsy. **Methods:** Forty patients (aged 1 month to 41 years) underwent MR scanning and findings were correlated with clinical histories in all cases. **Results:** Review of MR scans of 11 patients who had been born prematurely revealed findings of periventricular white matter damage, indicative of hypoxic-ischemic brain injury (82%), the chronology of which was difficult to determine. Among 29 patients who had been born at term, three major patterns emerged: (1), gyral anomalies, suggestive of polymicrogyria, consistent with mid-second trimester injury; (2), isolated periventricular leukomalacia reflecting late second- or early third-trimester injury; and (3), watershed cortical or deep gray nuclear damage, consistent with late third-trimester, perinatal or postnatal injury. In 16 (55%) of 29 patients born at term, MR findings of intrauterine brain damage were observed; in over half of these cases MR revealed developmental anomalies, which is nearly twice the rate reported in prior studies employing CT. **Conclusion:** Our results support a growing consensus that cerebral palsy in term infants is often the result of prenatal factors, and less commonly related to the perinatal period.

Index term: Cerebral palsy

AJNR 13:67-78, January/February 1992

Cerebral palsy (CP) has been the subject of numerous clinical, neuropathologic, and neuroradiologic studies to assess the relationship of pre-, peri-, and postnatal events to CP (1-9). Clinical studies have been limited by the availability of historical information regarding prenatal care and possible prenatal insults. Neuropathologic studies have been limited by the small

numbers of cases that have gone to autopsy. Neuroradiologic studies have been limited in their usefulness, primarily because of the limited capabilities of neuroimaging in the era before computed tomography (CT) and magnetic resonance (MR) imaging. With the development of CT, radiographic correlation with clinical data regarding prenatal, perinatal, and postnatal asphyxia became possible, particularly with respect to morphologic changes of the cerebral white matter (1, 7-10). The sensitivity of CT, however, is limited in many cases of cerebral palsy. In particular, while state-of-the-art CT is sensitive to dramatic anomalies of brain development, such as schizencephaly, MR is more sensitive than CT in the detection of both subtle brain malformations, such as callosal hypogenesis, polymicrogyria, and mild degrees of white matter damage. Therefore, we studied MR images to retrospectively analyze the brains of patients with cerebral palsy.

Materials and Methods

Forty patients, aged 1 month to 41 years, underwent MR scanning at either mid (0.35 T) or high (1.5 T) field

Received February 20, 1991; accepted and revision requested April 15, revision received May 22; final acceptance May 29.

The views expressed in this article are those of the authors and do not reflect the official policy or position of the Department of the Army, the Department of Defense, or the United States Government.

¹ U.S. Army Medical Department, Academy of Health Sciences, HSHA-GPS Fort Sam Houston, TX 78234-6100. Address reprint requests to C.L. Truwit, Department of Radiology, Fitzsimons Army Medical Center, Aurora, CO 80045-5000.

² Department of Radiology, Neuroradiology Section, University of California, San Francisco, 505 Parnassus Ave., Box 0628, San Francisco, CA 94143-0628.

³ Department of Pediatric Neurology, University of California, San Francisco, San Francisco, CA 94143.

⁴ Department of Pediatric Neurology, San Francisco General Hospital, San Francisco, CA 94110.

AJNR 13:67-78, Jan/Feb 1992 0195-6108/92/1301-0067

© American Society of Neuroradiology

strength. Three patients were initially scanned at less than 1 year of age. They are now 4 years, 6 months (case 15), 3 years, 4 months (case 24) and 2 years, 6 months (case 27) and have spastic, hypotonic and spastic CP, respectively. As the study was undertaken at a major referral center, the study population was limited by selecting only those patients with the referral diagnosis of CP, and only those for whom MR studies were included. The MR studies were retrospectively reviewed by two of the authors with knowledge of the preceding clinical diagnosis of CP, but without knowledge of the specific clinical manifestations of each case. Thus, the MR review was only partially blinded, since the diagnosis of CP was known. Nevertheless, because we set out to assess what abnormalities appeared on MR scans of patients with CP, not the efficacy of MR in diagnosing CP, we believe this methodology was appropriate.

All MR studies included sagittal and axial T1-weighted images, 400–800/20–35/1–2 (TR/TE/excitations), and axial T2-weighted images, 2000–3000/30–120/1–2. The MR studies were evaluated for developmental or acquired abnormalities of the corpus callosum, deep and peripheral white matter, cerebral cortex, basal ganglia/thalami, and brainstem, and for the presence of parenchymal cysts, hydrocephalus, and ventricular contour defects. The corpus callosum, brainstem, cerebral cortex, and basal ganglia/thalami were subjectively assessed as thinned or normal. As the radiologic manifestations of preterm and term injuries differ, patients born prematurely were grouped separately.

Classification of cerebral anomalies was based on typical MR findings. Polymicrogyria was diagnosed by the presence of abnormally thick cortex, diminished and absent arborization of subjacent white matter, and mild ventriculomegaly beneath the anomalous parenchyma (11, 12). Hypoplasia of the ipsilateral thalamus, cerebral peduncle, and pons was commonly associated. The cortical mantle typically demonstrated multiple sulci, in contradistinction to the broad, shallow gyri of pachygyria, and in contradistinction to the mushroom-shaped, small gyri of ulegyria. We recognize that this definition is broader than the strict pathologic definition, which requires an abnormal four-layered cortex. Nevertheless, although it is possible that the MR findings reflect another, unspecified migration anomaly, in our experience, this MR pattern has repeatedly correlated with pathologic specimens of polymicrogyria.

The diagnosis of schizencephaly required MR definition of an abnormal gray matter cleft extending all the way to the lateral ventricle. A cleft that reached toward, but that was clearly separated from, the ventricle was defined as a cleft of polymicrogyria (13). Although others have considered this to be type I schizencephaly (14), we consider the presence of white matter between the gray matter cleft and the lateral ventricle to distinguish the two entities, since a pial-ependymal seam, the hallmark of schizencephaly, is impossible in this situation.

MR findings were correlated with clinical histories, which were available for all patients. In one patient (case 4), no birth history was available other than delivery at 28 weeks

gestation. Specifically, pre-, peri- and postnatal histories were assessed. Eleven patients (27%) were born prematurely, by the criterion of a gestational age (by dates) of 36 weeks or less at the time of birth. Twenty-nine patients (73%) were delivered at or near term. Although included in Table 1, we did not segregate the patients by type of CP (e.g., diplegic, quadriplegic), as we commonly encountered clinical discrepancies, such as one clinician labeling the patient diplegic only to find the next clinician labeling the same patient quadriplegic or hemiplegic.

For purposes of this study, we defined the perinatal period as that time starting 2 weeks before birth and continuing through the first 2 weeks of life. Perinatal asphyxia was defined to include fetal distress and respiratory distress (endotracheal oxygenation, meconium aspiration, arrest, or near-arrest). We did not try to separate the types and degrees of perinatal asphyxia. Periventricular leukomalacia (PVL), isolated periventricular white matter damage without cortical, subcortical, or deep gray matter lesions, was considered to be representative of brain damage that occurred prior to the 36th week of gestation. This concept is supported by recent reports on the MR assessment of perinatal asphyxia (15, 16). As a result, isolated PVL in the term infant was considered to be consequent to intrauterine brain injury, even in the face of perinatal insults.

Results

As seen in Table 1, the MR scans revealed readily apparent abnormalities in every patient except three patients born at term. One of these patients (case 16) had choreoathetoid CP; her mother had experienced third-trimester pre eclampsia. Another patient (case 22) had spasticity and was cortically blind. The third patient (case 29) underwent meconium aspiration and had spasticity.

MR Findings in Patients Born Prematurely

Among the 11 patients born prematurely, several radiographic features were apparent. MR scans in all 11 revealed deep white matter loss, especially in the peritrigonal regions. In nine of the 11, scans demonstrated thinning of the corpus callosum, especially in the posterior body (Fig. 1). In case 8, the corpus callosum was severely hypogenetic. The one patient with a normal corpus callosum (case 5) had hypotonic CP and had diminished deep, and to a lesser extent peripheral, white matter. The ventricular trigones were slightly rounded. All had abnormal ventricles, usually manifested as irregular contour of the trigones, consistent with prior incorporation of periventricular cysts. One patient (case 9) had discrete periventricular cysts. In three patients (cases 5, 6, and 8), born at 30–32 weeks'

TABLE 1: Clinical and MR Findings in Patients with Cerebral Palsy

Group/ Case No.	Age at MR	Sex	Gestational Age at Birth: Peri- Postnatal History	Dominant Clinical Findings	Corpus Callosum	Deep White Matter	Peripheral White Matter	Cysts	Lateral Ventricles	Cortex	Basal Ganglia	Brainstem	Other Findings
Born prematurely													
1	9 yr, 8 mo	M	27 wk: Grade 4 intraventricular hemorrhage, shunt, RDS	Spastic diplegia	Diffusely thinned, especially posteriorly	Diminished, especially peritrigonal	Normal	No	Irregular contour, especially midbody and trigones	Normal	Normal	Normal	-
2	1 yr, 6 mo	F	28 wk: Grade 3 intraventricular hemorrhage, RDS	Spastic diplegia	Thinned posterior body	Diminished peritrigonal & long T2	Normal	No	Dilated trigones	Normal	Normal	Normal	-
3	1 yr, 2 mo	M	28 wk: RDS, intraventricular hemorrhage	Spasticity	Diffusely thinned, posterior > anterior	Diminished peritrigonal	Normal	No	Minimally irregular contour	Normal	Normal	Small	Cerebellar hemispheric hypoplasia vs atrophy
4	41 yr	F	28 wk	Spasticity, blindness	Thinned body	Diminished & long T2	Normal	No	Abnormal contour	Normal	Normal	Normal	-
5	2 yr, 6 mo	F	30 wk: Surviving twin; endotracheal intubation for 2 wk	Hypotonic, athetoid, paraparesis	Normal	Diminished peritrigonal & occipital	Slightly diminished	No	Slightly rounded trigones	Normal	Normal	Normal	-
6	7 yr, 5 mo	M	30 wk: Severe RDS, intraventricular hemorrhage, shunt	Spasticity, LE	Thinned posterior body & splenium	Diminished peritrigonal	Scattered foci of prolonged T2	No	Irregular contour posteriorly	Normal	Normal	Normal	-
7	2 yr, 8 mo	F	30-31 wk: 5 days' endotracheal intubation, ductus ligation	Spastic diplegia	Thinned posterior body & splenium	Diminished peritrigonal, long T2	Normal	No	Dilated trigones & occipital horns with irregular contour	Normal	Normal	Normal	-
8	10 yr	M	32 wk: NSVD, hydrocephalus noted at birth; shunt at 3 wk	Spastic diplegia, mental retardation	Severe hypogenesis	Markedly diminished	Mildly diminished posteriorly	No	Markedly irregular contour	Normal	Normal	Normal	Chiasmatic hypoplasia
9	2 yr	F	32 wk: Fetal distress precipitating emergency cesarean delivery; Apgars, 7/9	Spasticity	Thinned posterior body	Diffusely diminished & long T2	Normal	Yes, peritrigonal	Mild contour abnormality	Normal	Normal	Normal	-
10	3 yr, 8 mo	F	35 wk: Preeclampsia, fetal distress, cesarean delivery	Hypotonia, blindness	Severely thinned	Diminished; gliosis	Normal	No	Enlarged ex vacuo	Normal	Normal	Small	-
11	4 yr, 6 mo	M	36 wk: ? In utero toxoplasmosis, preeclampsia, fetal distress, cesarean delivery, hypoglycemia at birth	Spastic diplegia, L > R; developmental delay	Diffusely thinned body	Diffusely thinned & long T2	Normal	No	Minimally irregular contour, trigones	Normal	Normal	Small	-

TABLE 1: Clinical and MR Findings in Patients with Cerebral Palsy—Continued

Group/ Case No.	Age at MR	Sex	Gestational Age at Birth; Peri-, Postnatal History	Dominant Clinical Findings	Corpus Callosum	Deep White Matter	Peripheral White Matter	Cysts	Lateral Ventricles	Cortex	Basal Ganglia	Brainstem	Other Findings
Born at term													
12	1 yr, 1 mo	F	37 wk: Cyanosis at birth, oxygen for 24 hr	Hypotonia, severe developmental delay	Normal	Delayed myelination	Delayed myelination	No	Normal	Normal	Normal	Normal	—
13	2 yr	M	38 wk	Spasticity, R monoparesis	Thinned posterior body, splenium	Diminished peritrigonal & slight frontal	Normal	No	Abnormal contour	Normal	Normal	Normal	—
14	1 yr, 11 mo	M	38 wk	Spasticity, LE > UE	Mildly thinned posterior body & splenium	Peritrigonal thinning	Normal	No	Mildly irregular contour, trigone	Normal	Normal	Normal	—
15	11 mo	M	42 wk: Decreased fetal movements for 24 hr at 30 wk; Apgars: 7/8	Spasticity, R UE	Mildly thinned body	Diminished peritrigonal, L side	Normal	Yes	Irregular contour, L trigone	Normal	Infarcts, L internal capsule & thalamus	Atrophy, L cerebral peduncle	—
16	4 yr, 11 mo	F	Third-trimester pre-eclampsia: Apgars, 7/9	Choreoathetoid movements	Normal	Normal	Normal	No	Normal	Normal	Normal	Normal	—
17	4 yr	M	43 wk: Meconium staining; Apgars, 4/7	Spastic quadriplegia, seizures	Thinned body & splenium	Diminished peritrigonal	Slightly diminished	No	Slightly bulbous trigones	Normal	Thalami slightly small	Normal	—
18	3 yr, 3 mo	F	Term: Microcephalic, delayed delivery after twin requiring Pitocin, meconium staining	Spastic quadriplegia, R > L; developmental delay	Thinned body & splenium	Diminished diffusely with long T2	Diminished diffusely with long T2	No	Enlarged with abnormal contour	Thinned posterior parietal	Long T2, L thalamus & L putamen	Normal	—
19	6 yr, 11 mo	M	Term: Anoxia, meconium aspiration, microcephaly	Spastic hypertonic monoplegia, seizures, dystonia, severe mental retardation	Diffusely thinned	Diffusely thinned, L > R	Diffusely thinned, L > R	Multiple	Porencephaly, L > R, occipital > frontal	Diffusely thinned	Normal	Normal	Multicystic encephalomalacia, L > R
20	8 yr, 9 mo	F	Term	Spastic quadriplegia	Severely thinned diffusely	Very thinned diffusely	Very thinned diffusely	No	Enlarged	Diffusely thinned	Short T2	Normal	Short T2 subcortically, diffuse atrophy
21	11 yr	M	Term	Seizures, L hemiparesis	Thinned body	Schizencephaly into posterior limb	Schizencephaly into posterior limb	No	Abnormal contour, L side	Schizencephaly	Normal	Normal	—
22	4 yr	F	Term	Spasticity, cortical blindness	Normal	Normal	Normal	No	Normal	Normal	Normal	Normal	—
23	18 yr	F	Term: NSVD	Spastic quadriplegia, developmental delay	Normal	Normal	Focal T2 prolongation	No	Distorted body	Parietal polymicrogyria with cleft	Normal	Normal	—
24	1 mo	F	Term: Mild meconium staining, narrowly avoided SIDS, arrest on day 8	Hypotonic quadriplegia	Normal	Delayed myelination	None	No	Diffusely enlarged, L side	Normal	Clumped foci of T1 & T2 shortening	Thin mid-brain	—

TABLE 1: Clinical and MR Findings in Patients with Cerebral Palsy—Continued

Group/ Case No.	Age at MR	Sex	Gestational Age at Birth: Peri- Postnatal History	Dominant Clinical Findings	Corpus Callosum	Deep White Matter	Peripheral White Matter	Cysts	Lateral Ventricles	Cortex	Basal Ganglia	Brainstem	Other Findings
25	3 yr, 6 mo	M	Term: Normal until 6 mo	Spasticity, mental retardation, developmental delay	Thinned posterior body & splen- ium	Very delayed myelination	Very delayed myelina- tion	No	Bulbous frontal tips & trigones	Normal	Normal	Small	—
26	2 yr, 1 mo	F	Term: Apgars, 9/9	Spastic diplegia, truncal ataxia, ver- tical nystagmus, L side	Slightly thinned diffusely, but normal for de- layed myelina- tion	Delayed myelination	Delayed mye- lination; slightly prolonged T2, peritri- gonal	No	Normal	Normal	Normal	Normal	—
27	10 mo	M	Term: Spotting since first month, pre- mature rupture of membranes >36 hr, nuchal X2, home birth	Spastic diplegia, L hemiparesis	Thinned splen- ium	Long T1 & T2, trigonal, temporal, occipital	Diminished on R, bilateral subcortical encephalo- malacia, temporal tips	No	Enlarged temporal & occip- ital horns, trigones	Diffuse poly- micro- gyria, R frontal, parietal	Small R thalamus	Diffusely small, R side	—
28	1 yr, 7 mo	M	Term: Nuchal cord; Apgars, 9/9	Spastic diplegia	Thinned body & splenium	Diminished periventricu- lar & long T2	Normal	No	Probably normal	Normal	Normal	Normal	—
29	2 yr	M	Term: Meconium as- piration	Spasticity	Normal	Normal	Normal	No	Normal	Normal	Normal	Normal	—
30	6 yr, 6 mo	F	Term: NSVD, micro- cephaly	Developmental de- lay, L hemiparesis	Slightly short, al- though normal thickness	Diminished, R side	Diminished on R side; L parietal focus of long T2	No	Enlarged, R side	Diffuse poly- micro- gyria; R frontal, parietal	Small R thalamus	Diminish- ed R cerebral pedun- cle & pons	L temporal arachnoid cyst, brachycephaly
31	3 yr, 4 mo	F	Term: Dehydration at 3 wk	Motor delay	Normal	Peritrigonal diminished & long T2	Normal	No	Enlarged trigones & bodies	Normal	Normal	Small	Large sylvian fissure, brachycephaly
32	1 yr, 4 mo	F	Term: Apgars, 8/9	Seizures, L hemipa- resis	Normal	Diminished on R	Normal	No	Normal	R poly- micro- gyria	Normal	Normal	—
33	1 yr, 8 mo	F	Term: NSVD	Spasticity, R LE	Normal	Diminished	Diminished	Multiple subcor- tical	Abnormal contour, L side	L fronto- parietal polymy- crogyria	Normal	Normal	—
34	2 yr, 5 mo	M	Term: NSVD	Hypotonic	Normal	Diminished frontally; few foci of long T2	Normal	No	Mildly abnormal contour, L > R, trigones	Normal	Normal	Normal	Bilateral spandy gray matter hetero- topias
35	32 yr	F	Term	Spastic quadriple- gia, LE/UE; new seizures	Normal	Diminished frontally	Diminished frontally	No	Normal	Bifrontal polymy- crogyria	Normal	Normal	—
36	1 yr, 6 mo	M	Term: Apgars, 9/10; maternal hemor- rhage 69 days be- fore delivery	Spastic diplegia	Diffusely thinned	Diminished, peritrigonal > frontal; long T2	Normal	No	Normal	Normal	Normal	Normal	—

TABLE 1: Clinical and MR Findings in Patients with Cerebral Palsy—Continued

Group/ Case No.	Age at MR	Sex	Gestational Age at Birth: Peri- Postnatal History	Dominant Clinical Findings	Corpus Callosum	Deep White Matter	Peripheral White Matter	Cysts	Lateral Ventricles	Cortex	Basal Ganglia	Brainstem	Other Findings
37	5 yr, 8 mo	M	Term: Apgars, 4/5; birth asphyxia, two-vessel cord	Hypotonic quadri- plegia, seizures, choreiform move- ments	Thinned dorsum & splenium	Diminished peritrigonal	Normal	No	Abnormal contour	Normal	Normal	Mildly small	Small vermis
38	5 yr, 1 mo	F	Term: Stillborn twin	Spastic quadriple- gia, seizures, global developmental delay	Absent	Absent	Absent	-	-	Absent	Mostly ab- sent	Absent ventral, superior pons	Hydranencephaly
39	2 yr, 9 mo	M	Term: NSVD, apneic spells at 2 wk re- quiring endotra- cheal oxygenation	Spastic quadriple- gia, seizures, blindness	Diffusely thinned	Diffusely diminished & long T2	Diminished posteriorly	No	Enlarged, abnormal con- tour	Normal	Small basal ganglia & thalami	Normal	-
40	1 yr	M	Term: NSVD, fragile X, microcephaly	Spastic quadriplegia	Normal	Diminished peritrigonal & long T2	Diminished at regions of polymicro- gyria	No	Enlarged, abnormal con- tour	Bilateral parietal clefts of polymicro- gyria	Normal	Normal	-

Note:—R = right; L = left; yr = year; mo = month; wk = week; RDS = respiratory distress syndrome; LE = lower extremity; UE = upper extremity; NSVD = normal spontaneous vaginal delivery; SIDS = sudden infant death syndrome.

gestation, peripheral white matter damage was seen on MR. This is not typically observed prior to 34 weeks of gestation (16). Two of these three patients (cases 6 and 8) had been previously shunted for hydrocephalus; it is possible that the peripheral white matter damage was related to the hydrocephalus and/or shunting (17). The other patient was a twin, and it is possible that the gestational age was underestimated.

No abnormalities were noted in the basal ganglia or thalami. Three patients (27%) (cases 10 and 11) had diminished caliber of the brainstem. Three patients (27%) (cases 1, 6, and 8) had been shunted for hydrocephalus. Developmental anomalies were noted in one patient with severe hypogenesis of the corpus callosum and optic chiasmatic hypoplasia (case 8). There were no apparent significant morphologic differences between the spastic and hypotonic CP cases.

Clinical Findings in Patients Born Prematurely

Of the 11, nine (82%) had varying degrees of spastic CP (cases 1–4, 6–9, and 11) and two (18%) had hypotonic CP (cases 5 and 10). Nine patients (82%) had perinatal asphyxia (cases 1–3 and 5–10). One patient (case 11) had elevated serum titers of toxoplasmosis antibodies, as did the mother, which suggested intrauterine insult.

MR Findings in Patients Born at Term

The MR results in the 29 patients born at term were not as uniform as in those in the subgroup of patients born prematurely. Nineteen patients born at term (66%) had diminished deep white matter (cases 13–15, 17–21, 28, 30–37, 39, and 40) (Figs. 2 and 3), seven of whom also had prolonged T2 relaxation of the white matter (cases 18, 28, 31, 34, 36, 39, and 40) and six of whom had overlying anomalies of neuronal migration (cases 21, 30, 32, 33, 35, and 40) (Fig. 4). Three patients had abnormal signal of the white matter but normal white matter quantity: two had delayed myelination (cases 25 and 26) and one had foci of T2 prolongation (case 27).

Only six of the 22 patients with abnormal white matter had perinatal asphyxia (cases 18–19, 24, 27, 37, and 39), although one of the six (case 27) had clinical and MR findings of both intrauterine damage (neuronal migration anomaly) and perinatal damage (premature rupture of membranes and nuchal cord, abnormal peripheral white matter of the contralateral hemisphere) (Fig. 4). Five of the 22 had findings typical of PVL, manifested by involvement of the corpus callosum, deep

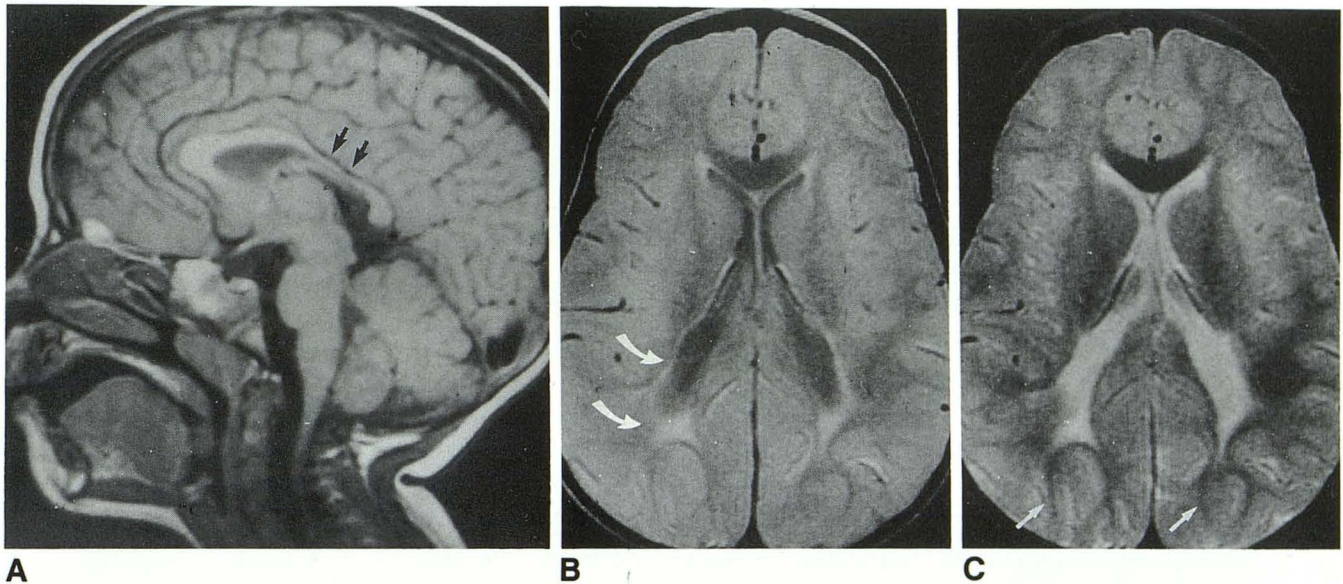


Fig. 1 Periventricular leukomalacia in patient born prematurely (case 7).

A, Sagittal T1-weighted image (600/20/1) reveals thinning of posterior callosal body (arrows) where peritrigonal fibers cross.

B and C, Axial proton-density- (2800/30/1) (B) and T2-weighted (2800/80/1) (C) images show diminished peritrigonal (deep) white matter and spared peripheral white matter (C, arrows). Note rounded contour of ventricular trigones and adjacent gliosis (B, arrows).

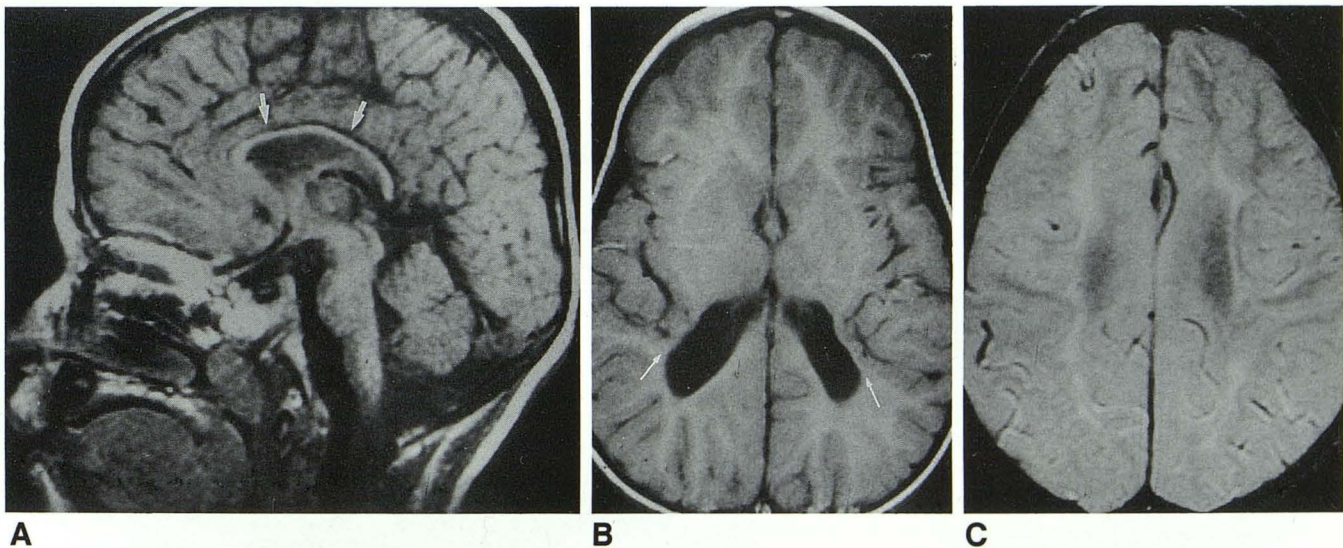


Fig. 2 Late third-trimester or perinatal asphyxia in patient born at term (case 39).

A, Sagittal T1-weighted image (600/20/1) shows diffuse callosal thinning (arrows).

B, Axial T1-weighted image (600/20/1) reveals apposition of posterior sylvian cortex to enlarged ventricular trigone, where marked loss of peritrigonal white matter is apparent (arrows). Ventricle has abnormal contour where periventricular cysts have been incorporated.

C, Axial proton-density image (2800/30/1) at most cephalad portion of lateral ventricles shows markedly diminished deep and peripheral white matter with abnormal T2 prolongation consistent with gliosis. Relatively normal peripheral white matter is seen in frontal lobes.

white matter, and ventricular-parenchymal interface. Of these five patients, one had clinical evidence of intrauterine insult (case 36), one had a two-vessel umbilical cord and perinatal asphyxia (case 37), and two had unremarkable

prenatal and perinatal histories (cases 13 and 14).

The corpus callosum was abnormal in 16 patients born at term (55%) (cases 13–15, 17, 21, 25–28, 30, 36, 37, and 39) (Figs. 2 and 3) and absent in one (case 38) (Fig. 4). In 15, the corpus

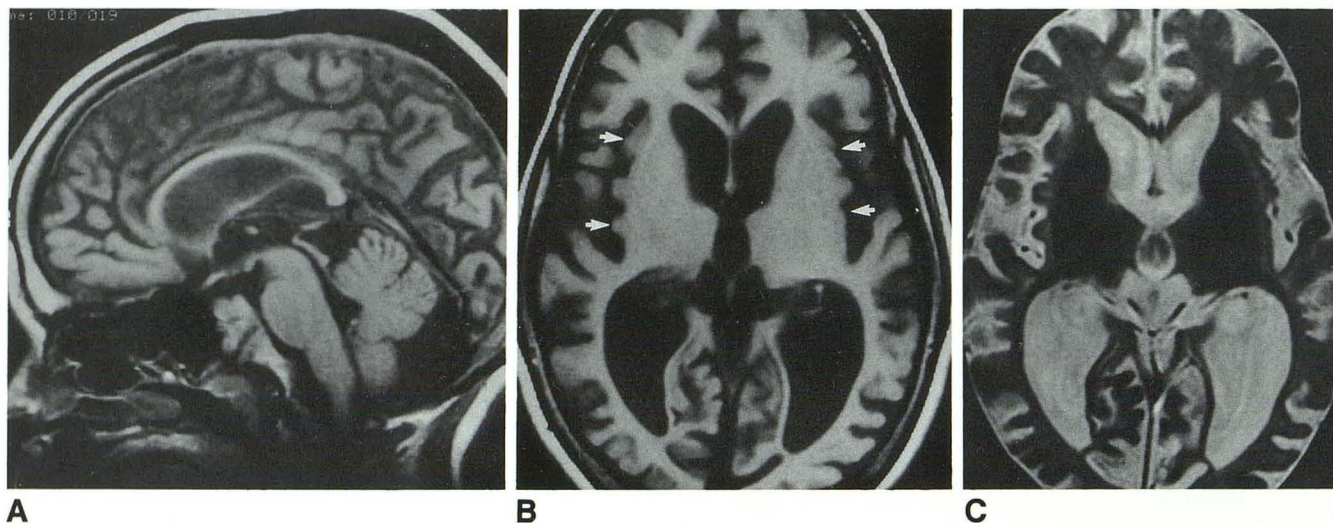


Fig. 3 Diffuse atrophy consistent with perinatal asphyxial event in patient born at term (case 20).
 A, Sagittal T1-weighted image (600/30/1) reveals diffuse callosal thinning and prominent CSF spaces.
 B, Axial image shows marked atrophy. Thinned cortex is well seen in sylvian region (*arrows*). Ventricles are enlarged ex vacuo.
 C, T2-weighted image (2800/80/1) confirms atrophy and reveals markedly diminished deep and peripheral white matter.

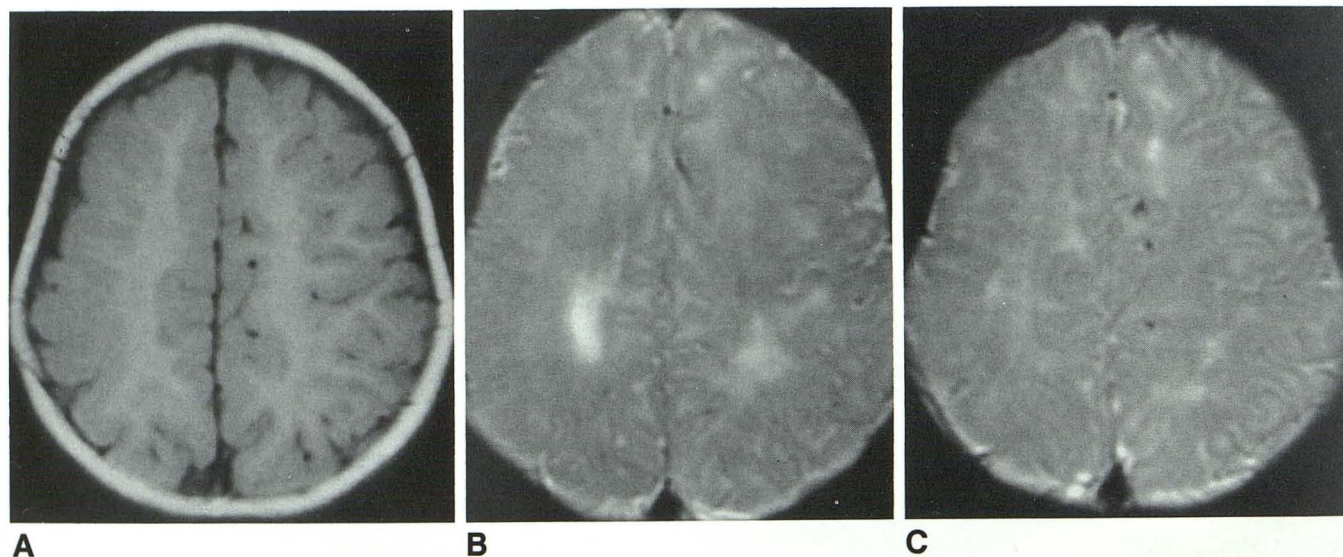


Fig. 4 Prenatal and perinatal insults in patient born at term (case 27).

A, Axial T1-weighted image reveals abnormal gyral pattern of right hemisphere and nearly complete absence of peripheral white matter on right. This image is typical of diffuse polymicrogyria, evidence of intrauterine insult. More caudal images (*not shown*) showed small right thalamus and cerebral peduncle and underdeveloped sylvian fissure. These findings are consistent with intrauterine brain damage.

B and C, Axial T2-weighted images (2800/80/1) show abnormal T2-prolongation of cerebral white matter. In particular, note abnormal signal on left side, uninvolved by polymicrogyria. Both deep and peripheral white matter are involved, consistent with clinical history of perinatal asphyxia in term infant.

callosum was thinned either focally (involving the posterior body and/or splenium) or diffusely. In one patient (case 30), the corpus callosum appeared foreshortened, although normal in shape and thickness.

Ventricular abnormalities were apparent in 20

patients born at term, including 12 (41%) with an irregular ventricular contour and ventricular enlargement, reflecting incorporation of parenchymal cysts or white matter hypoplasia (cases 13–15, 18, 19, 21, 23, 33, 34, 37, 39 and 40), seven (24%) with ventricular enlargement alone

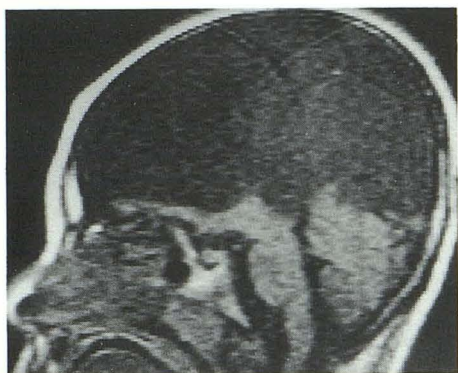

Fig. 5 Hydranencephaly in patient born at term (case 38). Sagittal T1-weighted image (600/30/1) reveals minimal subfrontal brain and otherwise absent supratentorial brain. Posterior fossa is normal.

(cases 17, 20, 24, 25, 27, 30, and 31), and one with hydranencephaly (case 38). Cortical thinning was seen in three term patients (10%) (cases 18–20), one of whom had findings diagnostic of multicystic encephalomalacia (case 19).

Six patients born at term had abnormalities of the basal ganglia and/or thalami (cases 15, 17, 24, 27, 30, and 39). Foci of marked T1 and T2 shortening in the basal nuclei, possibly representing hemorrhage, were apparent on the scan of one patient who had had perinatal asphyxia (case 24). Another patient (case 15), whose gestation had involved a 24-hr period of decreased fetal movements at 30 weeks, had a cyst involving the left thalamus and retrolenticular internal capsule with a small ipsilateral left cerebral peduncle. Clinically, there was spasticity of the right upper extremity. The third patient (case 17), born at 43 weeks with meconium staining, had bilaterally small thalami and slightly diminished peripheral white matter in addition to callosal and deep white matter thinning and bulbous ventricular trigones. Two patients (cases 27 and 30) had small right thalami, right frontoparietal anomalies of neuronal migration, and hypoplasia of the right brainstem. The gestation and birth in one of these patients (case 27) were complicated by vaginal spotting from the first month, premature rupture of membranes, a nuchal cord, and delivery at home. Clinically, the patient had spastic diplegia and superimposed left hemiparesis. The sixth patient (case 39) had postnatal apneic spells at 2 weeks, requiring endotracheal oxygenation. MR revealed small basal ganglia and thalami, as well as a diffusely thinned corpus callosum and diffusely diminished deep white matter, a constel-

lation of findings most consistent with anoxic brain damage (16).

Scans in 10 patients born at term (cases 21, 23, 27, 30, 32–35, 38, and 40) revealed developmental brain anomalies. Gyral anomalies suggestive of polymicrogyria were evident in eight (Fig. 4); one of these also demonstrated full-thickness porencephaly (schizencephaly) (13, 18). The scan in the ninth patient revealed gray matter heterotopias of the ventricular trigones (13, 18). Clinically, these nine patients had seizure disorders, spasticity or hemipareses, hypotonia, or a combination thereof. Birth histories were unremarkable in all, except for the patient who was born at home with a nuchal cord following premature rupture of membranes for greater than 36 hr (case 27). Finally, in a 5-year-old child with spastic quadriplegia, seizures, and global developmental delay, MR revealed hydranencephaly (Fig. 5).

Clinical Findings in Patients Born at Term

The clinical data of the 29 patients born at term revealed 21 patients (72%) with varying degrees of spastic CP; four (14%) with hypotonic CP, five (17%) with hemiparesis, either isolated or superimposed on spasticity; and one (3%) with choreoathetotic CP. Additionally, many patients were developmentally delayed (21%), had seizures (28%), or were cortically blind (7%). Two patients (cases 15 and 36) clinically had intrauterine insult. In both, MR findings suggested prenatal brain damage. Histories in six patients (cases 18, 19, 24, 27, 29, and 37) revealed perinatal asphyxia. Of these six, three (cases 18, 19, and 24) had MR findings suggestive of perinatal insult, one (case 38) had findings more suggestive of an intrauterine event, one (case 29) had a normal MR scan, and one (case 27) had findings of both intrauterine and perinatal asphyxia. Four more patients had clinical histories that may have been compatible with perinatal injury, although the clinical data did not meet our criteria for perinatal asphyxia. They included two with meconium staining (cases 16 and 17), one with a nuchal cord (case 28), and one born at 37 weeks who was cyanotic at birth and required 24 hr of oxygen therapy (case 12). Two patients had clinical histories suggesting postnatal injury, including one hospitalized for dehydration at 3 weeks (case 31) and one who had several apneic spells that required endotracheal oxygenation at 2 weeks of age (case 39). In the remaining patients

born at term, pregnancies and deliveries had been unremarkable.

Discussion

CP refers to a clinical set of static encephalopathies comprising a broad array of neuropathologies that are linked by their expression of variable disabilities of movement and posture. CP can be defined as a disorder of movement and posture consequent to a nonprogressive lesion of the immature brain (7, 19, 20). Several types of CP have been classified, of which spastic CP is the dominant type (21). In addition, choreoathetotic, hypotonic, and ataxic varieties have been described (21). Not infrequently, children with CP manifest overlap or evolution from one variety to another.

The first major study of children with CP dates to 1862, when Little reported 47 cases of persistent spastic rigidity in which abnormal circumstances attended the act of parturition (22). In particular, he focused on asphyxia neonatorum as the primary contributing factor. Since Little's work, the terminology has changed, such that persistent spastic rigidity is referred to as spastic CP, and asphyxia neonatorum has become perinatal asphyxia. What has endured, however, is the general perception in the medical, legal, and lay communities that CP is oftentimes consequent to perinatal asphyxia (19). (Note.—While Little's was the first large study, earlier reports by Pinel and Cazauvieilh had already addressed what would later be called CP. In addition, Little's lectures in 1843 formed the foundations of his later work (1, 2, 16).)

A neuropathologic classification of CP was first proposed by Freud, who distanced himself from Little by recognizing the etiologic significance of prenatal, perinatal, and postnatal brain insults (21, 23). Since Freud's contribution, abundant literature has focused on CP (2–7, 9, 15, 19, 20, 23–28). Whether studied from a neuropathologic, clinical, or even radiologic vantage, the underlying thematic questions have been: "What causes CP?" "How much of CP can be attributed to perinatal asphyxia?" and, in particular, the question of Hall (19), "How may the cases that are caused by 'asphyxia' be identified?" Recently, major epidemiologic studies have been published that contradict Little's hypothesis. In the Collaborative Perinatal Project of the National Institute of Neurological and Communicative Disorders

and Stroke, Nelson and Ellenberg (6, 28) concluded that "the proportion of CP associated with intrapartum asphyxia . . . was in the range of 3% to 13% and did not exceed 21%." In a study of the Western Australia Cerebral Palsy Register, Blair and Stanley (2) estimated intrapartum brain injury to be possible or likely in 4.9–8.2%.

In the present study, we sought to establish a role for MR in assessing brain damage in patients with CP. We started with the premise that all cases referred for study with the clinical diagnosis of CP qualified as case material. It became evident very early that cases were being included that by neurologic and neuropathologic criteria would have been excluded from earlier studies. Three patients with developmental delay or seizures, but lacking motor impairments, were excluded from the present study, despite referral diagnoses of CP. On the other hand, several cases with undeniable clinical manifestations of CP proved to have anomalies of brain development. We justify the inclusion of these cases on the grounds that, clinically, these patients cannot be differentiated: all have static, usually spastic encephalopathies with variable developmental delay and cognitive dysfunction. Despite the valuable contributions of earlier studies by Benda, Nelson and Ellenberg (6), and Adsett et al (1), patients with malformations of the central nervous system (CNS) were excluded from their populations of patients with CP (1, 6, 23). By such exclusion, a considerable portion of static encephalopathies are neglected, and attribution of CP to factors other than prenatal injury increases.

Patients were segregated into two subgroups based on gestational age at birth. The first group included 11 patients born prematurely (27%). This is consistent with the findings of earlier studies, such as that by Eastman and DeLeon (4), which found 35% of CP cases in preterm deliveries. Nine of the 11 patients in this group manifested typical MR findings of PVL (15, 16, 29). Eight of these nine cases had clinical evidence of perinatal asphyxia; in one patient no history was available. In only one of the 11 cases was a congenital malformation of the CNS (callosal hypogenesis) or extra-CNS organs noted.

Because the pattern of brain injury is similar in fetuses and neonates of 27–34 gestational weeks (16), it is not possible, on the basis of MR findings, to separate brain injury that occurred in utero (and may have predisposed these infants to premature birth) from perinatal or postnatal asphyxic events. As a result, it is conceivable that some of

the nine patients born prematurely with PVL had intrauterine events that predisposed the infants to prematurity. If so, perinatal asphyxia may not have been the sole insult resulting in brain injury.

In the second subset of 29 patients born at term (73%), a wide variety of abnormalities were observed. Most striking was the finding that, in 16 (55%) of the 29 patients, the MR scans revealed changes compatible with intrauterine insult to the developing brain. This included nine patients with anomalies of neuronal migration, one with hydranencephaly, five with PVL similar to that seen in premature infants, and one with findings of PVL and small infarcts of the left retrolenticular internal capsule and thalamus. Of these 16 patients, 10 had unremarkable gestational and birth histories, two had documented intrauterine insults, and three had histories pertinent to the perinatal period, although only two of these 16 patients are likely to have suffered perinatal asphyxia.

In contradistinction to the high percentage of intrauterine injuries in patients born at term, MR findings suggested perinatal brain injury in only seven (24%). This subset included the patients with focal deep gray matter injury, diffuse white matter diminution and parietal cortical thinning, multicystic encephalomalacia, diffuse parasagittal cortical and white matter injury, hemorrhage within the lentiform nuclei, small basal ganglia and/or thalami with callosal thinning and white matter loss, and the one with MR features of both intrauterine damage (polymicrogyria) and perinatal asphyxia (prolonged T2 relaxation of the deep and peripheral white matter bilaterally). In five of these seven patients, a history consistent with significant perinatal injury was present.

By cross-referencing the clinical data and MR findings, in only seven (24%) of the 29 patients born at term were we able to identify CP associated with perinatal asphyxia. Moreover, two of the seven had evidence of both intrauterine and perinatal brain damage. In most cases, therefore, neither clinical evidence nor MR findings of perinatal asphyxia could be identified. In 16 (55%) of 29 patients born at term, clinical and/or MR evidence of prenatal brain damage was present. In two cases (7%), brain damage most likely occurred in the postnatal period.

The high percentage of cases with intrauterine brain damage (55% of term patients, 9% of preterm, 43% of both term and preterm patients combined) was quite remarkable. Even excluding the cases of PVL in term infants, which we believe

should be classified as intrauterine insults, 10 term and one preterm cases of congenital malformations (28%) must be accounted for. Most of these patients had a gyral pattern suggestive of polymicrogyria, an anomaly of neuronal migration that occurs at approximately 20–22 weeks' gestation (13). In the postmortem study of Malamud et al. (3), 35% of patients with CP had CNS malformations: 10% had specific anomalies and 25% had microscopic aberrations of the CNS. A more recent clinical study of diplegic CP found seven (14%) of 49 term and one (2%) of 47 preterm patients to have CNS malformations, although no specific mention was made as to how these malformations were discovered (20). Several recent radiologic studies also found CP patients with developmental brain anomalies (7, 15). In a CT study of CP patients, Kolawole et al (9) found 15.8% of their patients had underlying prenatal (developmental) factors. Similarly, Wiklund et al (7) observed anomalies of neuronal migration on CT in 16% of their cases of congenital hemiplegia. Interestingly, they also found *periventricular atrophy* (roughly equivalent to our definition of PVL) in 42%. In an MR study, Koeda et al (15) found two (29%) of seven patients born at term with spastic diplegia had brain anomalies, one of whom had schizencephaly and contralateral polymicrogyria. The findings of our study and that of Koeda et al are not surprising because MR is known to be more sensitive than CT in the detection of subtle gyral anomalies.

In conclusion, although our study is limited by its retrospective nature and selected population, our results support an enlarging consensus that the group of patients with clinical CP consequent to intrauterine brain injury has been underemphasized in the past (7). With the increased sensitivity of MR in the detection of subtle brain injuries, a significantly higher proportion of CP patients may be determined to have suffered intrauterine brain damage. In light of these findings, CP should not be assumed to be consequent to a perinatal event; rather, consideration of prenatal, and occasionally postnatal, causes may be productive in determining the time of the brain injury. In furtherance of this search, MR imaging may be very helpful in cases of CP.

References

1. Adsett DB, Fitz CR, Hill A. Hypoxic-ischemic cerebral injury in the term newborn: correlation of CT findings with neurologic outcome. *Dev Med Child Neurol* 1985;27:155–160

2. Blair E, Stanley FJ. Intrapartum asphyxia: a rare cause of cerebral palsy. *J Pediatr* 1988;112:515-519
3. Malamud N, Itabashi HH, Castor J, Messinger HB. An etiologic and diagnostic study of cerebral palsy. *J Pediatr* 1964;65(2):270-293
4. Eastman NJ, DeLeon M. The etiology of cerebral palsy. *Am J Obstet Gynecol* 1955;69:950-961
5. Hagberg B, Hagberg G. Prenatal and perinatal risk factors in a survey of 681 Swedish cases. *Clin Dev Med* 1984;87:126-134
6. Nelson KB, Ellenberg JH. Antecedents of cerebral palsy: multivariate analysis of risk. *N Engl J Med* 1986;315:81-86
7. Wiklund L-M, Uvebrant P, Flodmark O. Morphology of cerebral lesions in children with congenital hemiplegia. *Neuroradiology* 1990;32:179-186
8. Kulakowski S, Larroche J-C. Cranial computerized tomography in cerebral palsy. An attempt at anatomic-clinical and radiological correlation. *Neuropediatrics* 1980;11:339-353
9. Kolawole TM, Patel PJ, Mahdi AH. Computed tomographic (CT) scans in cerebral palsy (CP). *Pediatr Radiol* 1989;20:23-27
10. Ando Y, Eda I, Nakano C, et al. Cranial computerized tomography of prematurely born children with cerebral palsy. *Acta Neonatol Jpn* 1985;21:281-287
11. Osborn RE, Byrd SE, Naidich TP, Bohan TP, Friedman H. MR imaging of neuronal migrational disorders. *AJNR* 1988;9:1101-1106
12. Smith AS, Blaser SI, Ross JS, Weinstein MA. Magnetic resonance imaging of disturbances in neuronal migration: illustration of an embryologic process. *RadioGraphics* 1989;9(3):509-522
13. Barth PG. Disorders of neuronal migration. *Can J Neurol Sci* 1987;14:1-16
14. Bird CR, Gilles FH. Type I schizencephaly: CT and neuropathologic findings. *AJNR* 1987;8:451-454
15. Koeda T, Suganuma I, Kohno Y, Takamatsu T, Takeshita K. MR imaging of spastic diplegia. *Neuroradiology* 1990;32:187-190
16. Barkovich AJ, Truwit CL. Brain damage from perinatal asphyxia: correlation of MR findings with gestational age. *AJNR* 1990;11:1087-1096
17. Weller RO, Williams BN. Cerebral biopsy and assessment of brain damage in hydrocephalus. *Arch Dis Child* 1975;50:763-768
18. Barkovich AJ. *Pediatric neuroimaging*. New York: Raven, 1990
19. Hall DMB. Birth asphyxia and cerebral palsy. *BMJ* 1989;299:279-282
20. Veelken N, Hagberg B, Hagberg G, Olow I. Diplegic cerebral palsy in Swedish term and preterm children: differences in reduced optimality, relations to neurology and pathogenetic factors. *Neuropediatrics* 1983;14:20-28
21. Ingram TTS. A historical review of the definition and classification of the cerebral palsies. *Clin Dev Med* 1984;87:1-11
22. Little WJ. On the influence of abnormal parturition, difficult labour, premature birth and asphyxia neonatorum on mental and physical conditions of the child, especially in relation to deformities. *Trans Obstet Soc London* 1862;3:293-344
23. Christensen E, Melchior JC. Cerebral palsy: a clinical and neuropathological study. *Clin Dev Med* 1967;25:1-14
24. Lilienfeld AM, Parkhurst EA. A study of the association of factors of pregnancy and parturition with the development of cerebral palsy. *Am J Epidemiol* 1951;53:262-282
25. Jarvis SN, Holloway JS, Hey EN. Increase in cerebral palsy in normal birthweight babies. *Arch Dis Child* 1985;60:1113-1121
26. Stanley FJ, Watson LD. The methodology of a cerebral palsy register: the Western Australian experience. *Neuroepidemiology* 1985;4:146-160
27. Stanley FJ. The changing face of cerebral palsy? *Dev Med Child Neurol* 1987;29:263-265
28. Nelson KB. What proportion of cerebral palsy is related to birth asphyxia? *J Pediatr* 1988;112:572-573
29. Flodmark O, Lupton B, Li D, et al. MR imaging of periventricular leukomalacia in childhood. *AJR* 1989;152:583-590

Note: Please see the Commentary by Volpe on page 79 in this issue.