

Aortic Valve Repair

Munir Boodhwani, MD, MMSc,^{*,†} and Gebrine El Khoury, MD*

Aortic valve replacement remains the gold standard for the treatment of severe aortic valve disease. However, valve repair is emerging as a feasible and attractive alternative to valve replacement in selected patients. Valve repair can

reduce or eliminate the risks of prosthesis-related complications including thromboembolism, endocarditis, anticoagulant-related hemorrhage, and reoperation due to structural valve deterioration, among others. Analogous to the mitral valve, a reconstructive approach to the aortic valve requires a thorough and detailed understanding of the valve anatomy, valve function, assessment, and classification of pathologic lesions, and treatment of all affected components of the valve. In this illustrative article, we describe key features of aortic valve and root anatomy, our approach to valve assessment and lesion classification, and a demonstration of commonly used reparative techniques for aortic valve repair.

*Department of Cardiovascular and Thoracic Surgery, Cliniques Universitaires Saint-Luc, Brussels, Belgium.

†Division of Cardiac Surgery, University of Ottawa Heart Institute, Ottawa, Canada.

Address reprint requests to Munir Boodhwani, MD, MMSc, Service de Chirurgie Cardiovasculaire et Thoracique, Cliniques Universitaires Saint-Luc UCL 90, Avenue Hippocrate 10, Brussels B-1200, Belgium.
E-mail: mboodhwani@ottawaheart.ca

Aortic Valve Anatomy and Lesion Classification

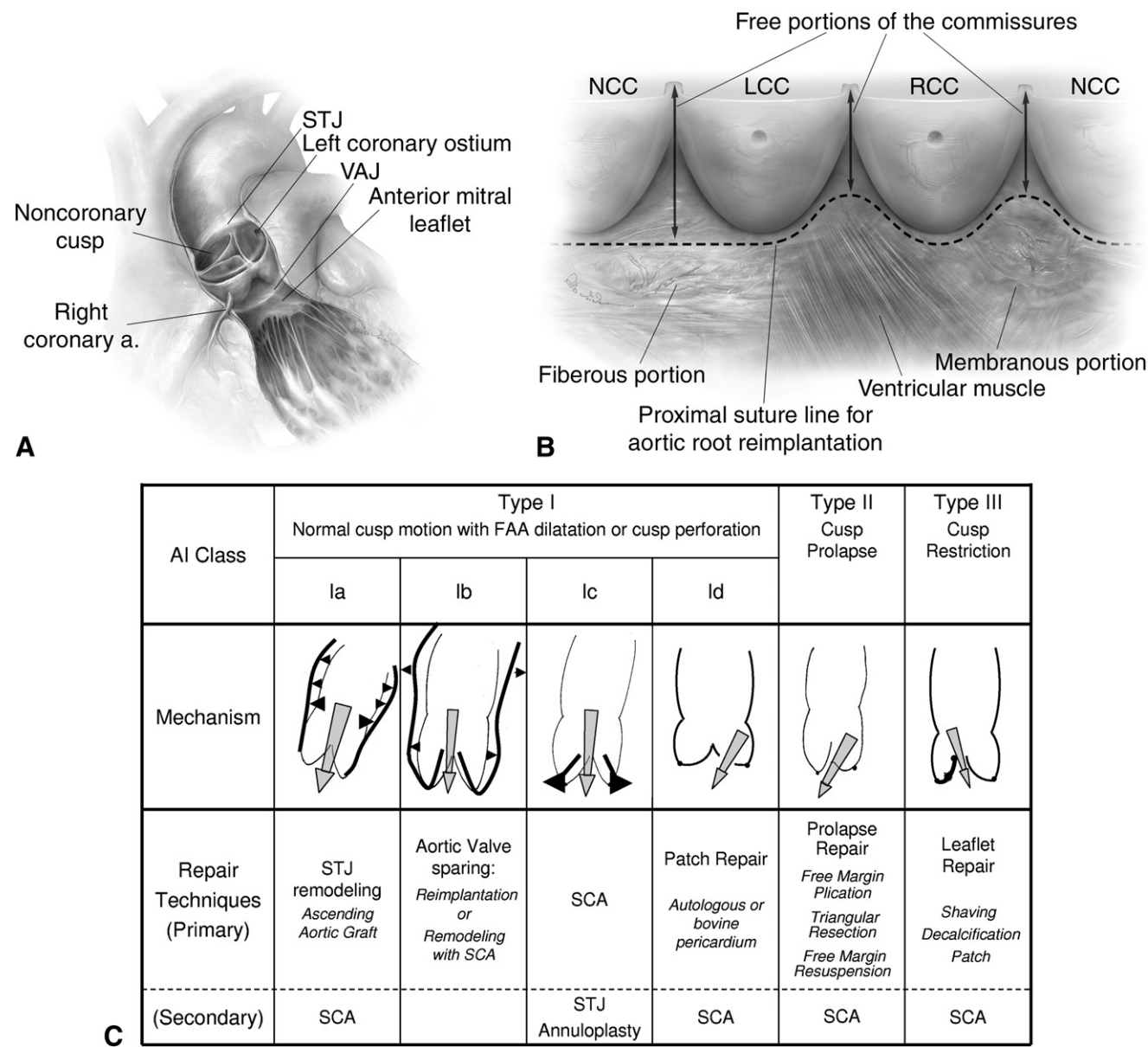


Figure 1 (A) Like the mitral valve, aortic valve function involves an important interaction between the valve annulus and leaflets. Importantly, however, the annulus of the aortic valve is not a single structure but rather consists of three different components, namely, the sinotubular junction, the ventriculo-aortic junction, and the anatomic crown-shaped annulus, which serves as the insertion point of the aortic valve cusps. These components work together to facilitate normal valve function and together are termed the “functional aortic annulus.” (B) The anatomy of the subvalvular region of the aortic valve and its surrounding structures also has important implications for aortic valve repair. The first observation is that external dissection of the aortic root from its surrounding structures is limited by the membranous septum (at the junction of the noncoronary and right coronary cusps) and by ventricular muscle (at the junction of the left and right coronary cusps), whereas, at all other points, external dissection down to the level of the anatomic valve annulus is possible and necessary when valve-sparing root replacement is performed using the reimplantation technique. Thus, the proximal suture line for the aortic valve reimplantation procedure follows these external limitations in a curvilinear fashion (dotted line). (C) Identification and classification of pathologic lesions that cause aortic insufficiency is critical to the appropriate application of repair techniques to the aortic valve. Our classification of aortic insufficiency encompasses all the mechanisms of aortic insufficiency, provides a common language for discussion among clinicians, and guides the repair techniques.² In this classification (as in the mitral valve), AI associated with normal leaflet motion is designated as type 1 and further divided into subtypes based on the specific pathologic condition. Type 2 AI is due to excessive cusp motion, ie, cusp prolapse, and type 3 AI is due to restrictive cusp motion as seen in rheumatic disease and in bicuspid aortic valves. a. = artery; AI = aortic insufficiency; FAA = functional aortic annulus; LCC = left coronary commissure; NCC = noncoronary commissure; RCC = right coronary commissure; SCA = sub-commissural annuloplasty; STJ = sinotubular junction; VAJ = ventriculo-aortic junction.

Aortotomy and Exposure

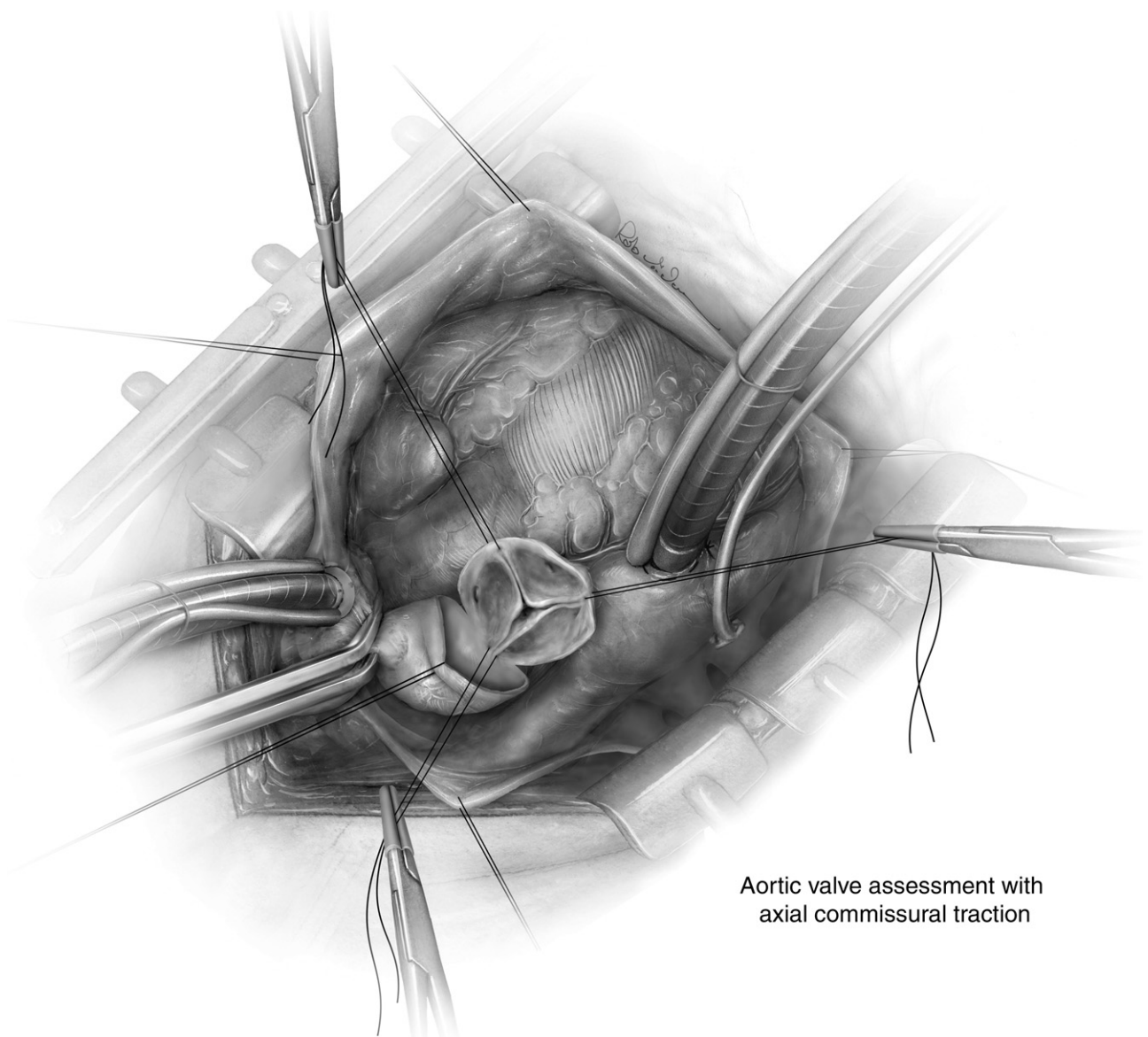


Figure 2 The distal ascending aorta (or transverse aortic arch) and right atrium are cannulated. Following cardioplegia administration, a transverse aortotomy is performed ~1 cm above the sinotubular junction starting above the noncoronary sinus and the posterior 2 to 3 cm of aortic wall is left intact. The distal aorta is retracted cephalad. Full-thickness 4-0 polypropylene traction sutures are placed at the three commissures and retracted using clamps but not tied to permit a dynamic assessment of valve anatomy. Axial traction is applied (perpendicular to the level of the annular plane) on the commissural traction sutures. This maneuver demonstrates physiological aortic valve closure position and the area and height of coaptation is observed. A prolapsing cusp will exhibit a transverse fibrous band at this time.

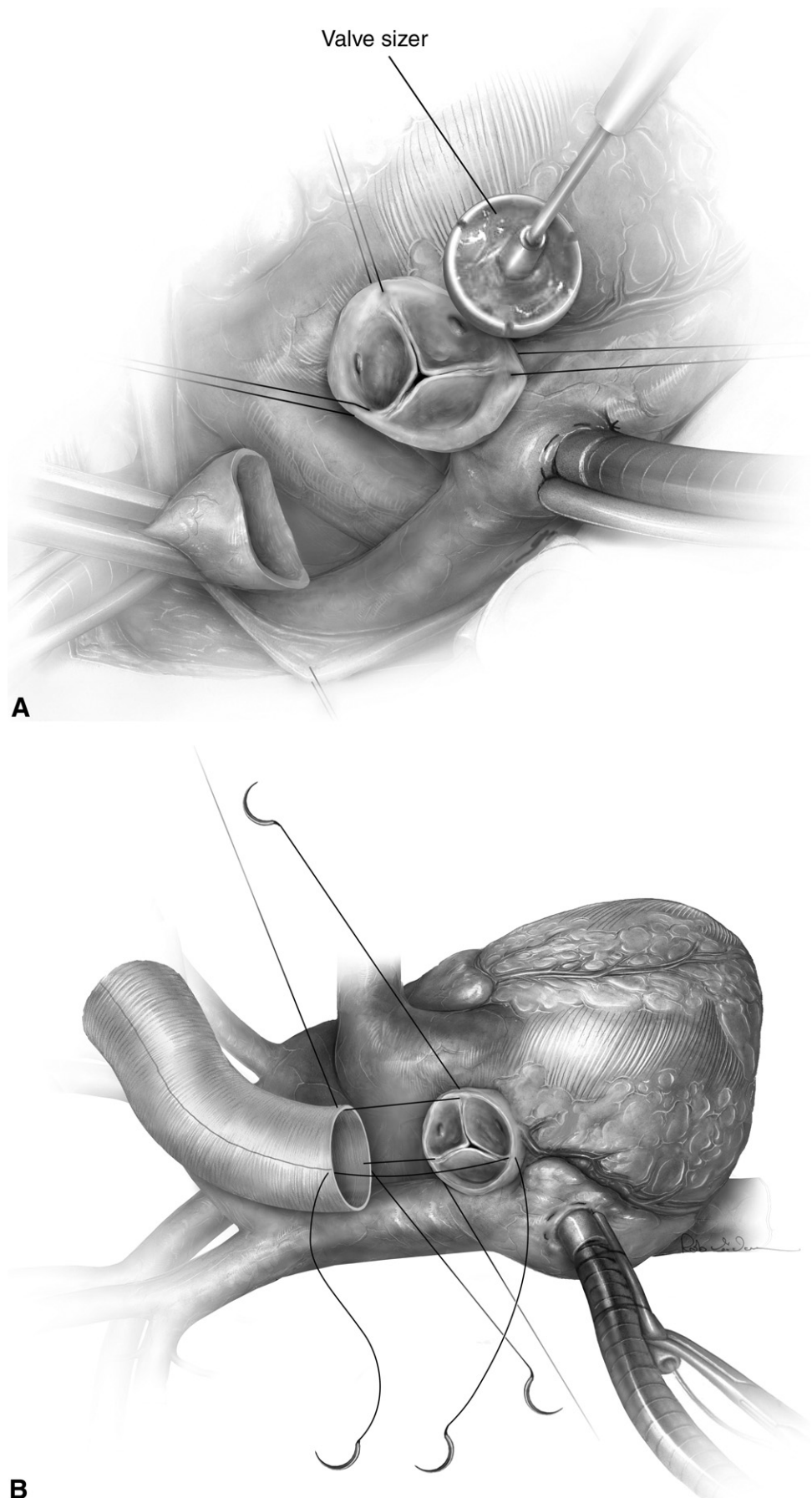
Surgical Techniques for Functional Aortic Annuloplasty

Type 1 lesions are most frequently due to dilation of the various components of the functional aortic annulus and may occur in isolation or in association with cusp disease. A type 1a lesion occurs due to a supracoronary ascending aortic aneurysm with concomitant dilation of the sinotubular junction (STJ). This is corrected by replacing the ascending aorta and remodeling the STJ using a Dacron tube graft ([Fig. 3](#)).

When significant associated aortic insufficiency (AI) is present, subcommissural annuloplasty is also performed as described in [Figure 4](#). Aneurysms of the aortic root (type 1b) are frequently associated with dilation of the STJ and the aorto-ventricular junction (AVJ). These are treated using valve-sparing root replacement, preferentially using the re-implantation technique because it provides better stabilization of the VAJ. The important steps of the valve-sparing procedure are described in [Figure 5](#) and supplemental videos.

Supracoronary Ascending Aortic Replacement

Figure 3 (A) Sizing of aortic prosthesis. Traction is applied to the commissural retraction sutures to place the valve in physiologic closing position with adequate cusp coaptation. The sinotubular junction is sized in this position. Oversizing the prosthesis can lead to central regurgitation, whereas undersizing can induce cusp prolapse. (B) Orientation and spacing. The anastomosis is performed at the level of the sinotubular junction starting with three separate sutures, one at each commissure. This ensures correct orientation of the prosthesis and appropriate spacing. Unequal spacing between commissures can induce cusp prolapse.



Subcommissural Annuloplasty

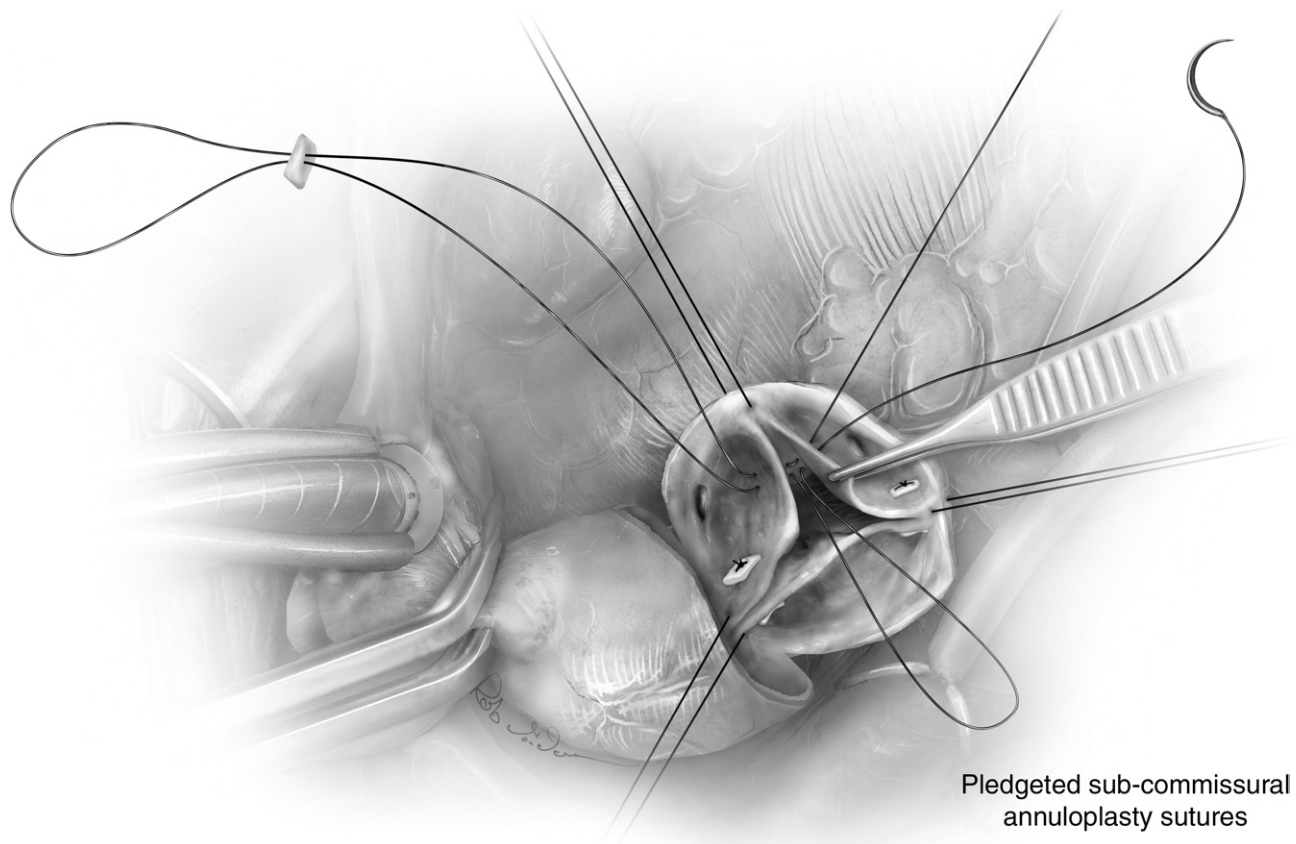


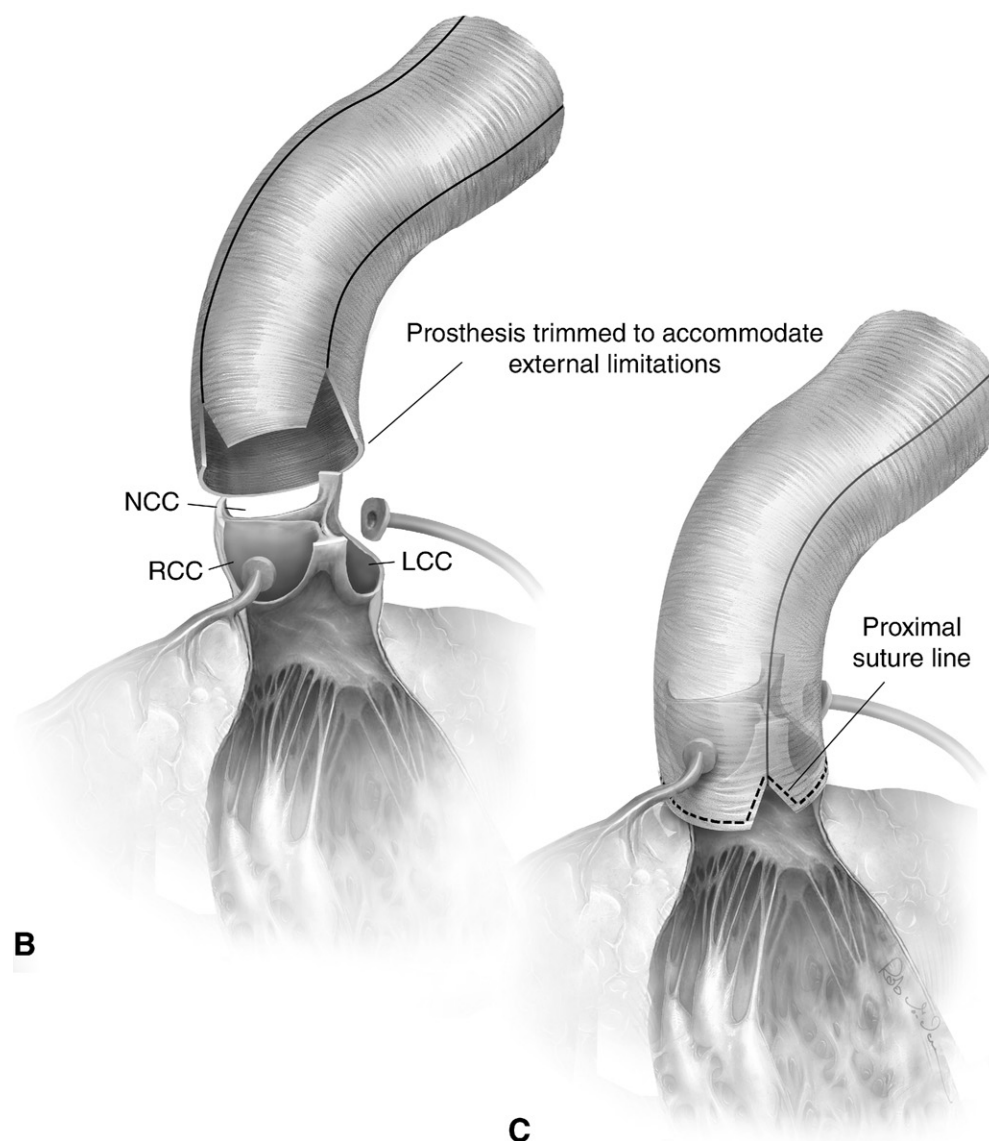
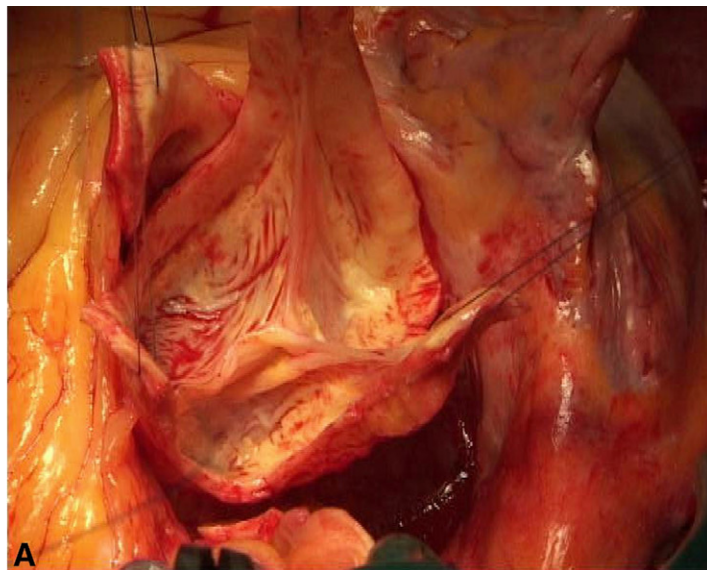
Figure 4 Subcommissural annuloplasty is performed using braided sutures. The first arm of the suture is passed from the aortic to the ventricular side, in the interleaflet triangle, and comes back out to the aortic side at the same level. The second arm of the suture is passed in a similar fashion just below the first. A free pledget is added and the suture is tied. This maneuver helps to stabilize the ventriculo-aortic junction, reduces the width of the interleaflet triangles, and increases the coaptation surface of the valve leaflets.

Subcommissural annuloplasty is typically performed at midcommissural height, except at the noncoronary/right coronary commissure, where it should be performed higher to avoid the membranous septum and conduction tissue. Care

should also be taken in this area during tying of the suture to avoid a tear in the septum. At the other two commissures, the subcommissural annuloplasty may be performed at a lower level if greater increase in the coaptation surface is desired.

Valve-Sparing Aortic Root Replacement–Reimplantation Technique: Step by Step

Figure 5 (A) The three commissural traction sutures are pulled perpendicular to the annular plane with a slight inward motion to ensure good leaflet coaptation. When the leaflets are coapting adequately, a Hagar dilator is used to size the circle that includes the three commissures and a graft 4 mm larger is chosen as this graft will sit outside the commissural posts. (B) To prevent AI, the three commissures must be attached to the prosthesis along the same plane, the new sinotubular junction. Due to external limitations of root dissection, the graft has to be tailored. First, the distance from the base of the interleaflet triangle to top of the commissure is measured at the LC/NC commissure and marked on the graft. Then, at the RC/NC and RC/LC commissures, the distance from the proximal suture to the top of the commissure is measured and used to determine the amount of graft material that needs to be trimmed. Thus, the height of the trimmed portion is the difference between height of the unrestricted LC/NC commissure and the distance from the proximal suture line to the top of the respective commissure. The pledgeted sutures are then passed through the base of the prosthesis, respecting the spaces between sutures and, importantly, the curvilinear contour of the suture line. The commissural traction sutures are pulled up together while tying down the prosthesis to ensure appropriate seating around the aortic annulus. LCC = left coronary commissure; NCC = noncoronary commissure; RCC = right coronary commissure. (Color version of figure is available online at <http://www.optechtc.com>.)



In addition to replacing a diseased aortic root, a valve-sparing root replacement using the reimplantation technique also serves as an annuloplasty of the aortic valve as it stabilizes the VAJ and STJ and protects against further dilation. Our approach to this procedure has been previously described,¹ but key aspects are highlighted below.

Root Dissection

The key principle is to externally dissect the aortic root as low as possible, given the natural anatomic limitations, ie, where the root inserts into ventricular muscle (Fig. 1B) (Video 1; supplementary video is available online at <http://www.optechtcs.com>). The root dissection is started along the non-coronary (NC) sinus and continued toward the left coronary (LC)/NC commissure. In this area, the subannular region of the aortic valve (AV) is fibrous and dissection can therefore be carried to below the level of insertion of the leaflets. Moving toward the right coronary (RC)/NC commissure as well as along the right sinus and the RC/LC commissure, the dissection is limited by nonfibrous portions of the annulus. The sinuses of Valsalva are then resected, leaving approximately 5 mm of aortic wall attached, and the coronary buttons are harvested.

Prosthesis Sizing

See Fig. 5A.

Proximal Suture Line

2-0 braided sutures with pledgets are passed from inside to outside the aorta with the pledgets on the inside, starting from the NC/LC commissure and moving clockwise. Along the fibrous portion of the aortic annulus, these sutures are inserted along the horizontal plane formed by the base of the interleaflet triangles. Importantly, however, along the nonfibrous portions of the annulus where the external dissection of the aortic root is limited by muscle, these sutures are inserted along the lowest portion of the freely dissected aortic root, making the proximal suture line slightly higher at the RC/NC and RC/LC commissures compared with the LC/NC commissure (Fig. 1B).

Prosthesis Preparation

See Fig. 5B.

Valve Reimplantation

The commissures are reimplanted first using 4-0 polypropylene sutures while pulling up on the prosthesis and the native commissure and then tied into place (Video 2; supplementary video is available online at <http://www.optechtcs.com>). Radial traction is then applied on two adjacent commissural sutures; this clearly delineates the “line of implanta-

tion.” This running suture line is performed in small regular steps passing the suture from outside the prosthesis to inside and through the aortic wall, staying close to the annulus, and then back out of the prosthesis.

Leaflet Assessment and Repair

After valve reimplantation, it is critical to re-examine the leaflets for any unmasked prolapse and symmetry, and the height and depth of coaptation. Prolapse can be repaired using a variety of techniques including leaflet resection, free margin plication, or free margin resuspension as described below. Cardioplegia is administered through the distal end of the graft with partial clamping to distend the new aortic root and assess root pressure and signs of left ventricle dilation. A limited echocardiographic view may be obtained at this time. The cardioplegia solution is then slowly aspirated out of the prosthesis without distorting the leaflets. This gives another visual assessment of the AV in its physiologic closed state as well as the area and height of coaptation.

Considerations for Bicuspid Valves

Prosthesis sizing tends to be somewhat larger for bicuspid than for tricuspid aortic valves to accommodate the typically larger VAJ. During prosthesis preparation, the graft is tailored to be symmetric (ie, 180°) around the two cusps regardless of the native valve anatomy (which may be asymmetric in type 1 valves). During valve reimplantation, the pseudocommissure is reimplanted at the same level as in the native valve. Alteration of the height of the pseudocommissure can cause cusp restriction.

Cusp Repair: Tricuspid Aortic Valves

Cusp prolapse is associated with excess length of the free margin, which can be corrected using either central free margin plication or free margin resuspension. When a single cusp is prolapsing, the two nonprolapsing cusps serve as the reference and are used to estimate the required reduction in the free margin length. When two cusps are prolapsing, the third nonprolapsing cusp is used as a reference to indicate the desired height of coaptation. In the rare instance that all the cusps are prolapsing, the goal is to achieve a cusp coaptation height at the midlevel of the sinuses of Valsalva.

Free Margin Plication

See Fig. 6.

Free Margin Resuspension

See Fig. 7 and Video 3 (supplementary video is available online at <http://www.optechtcs.com>).

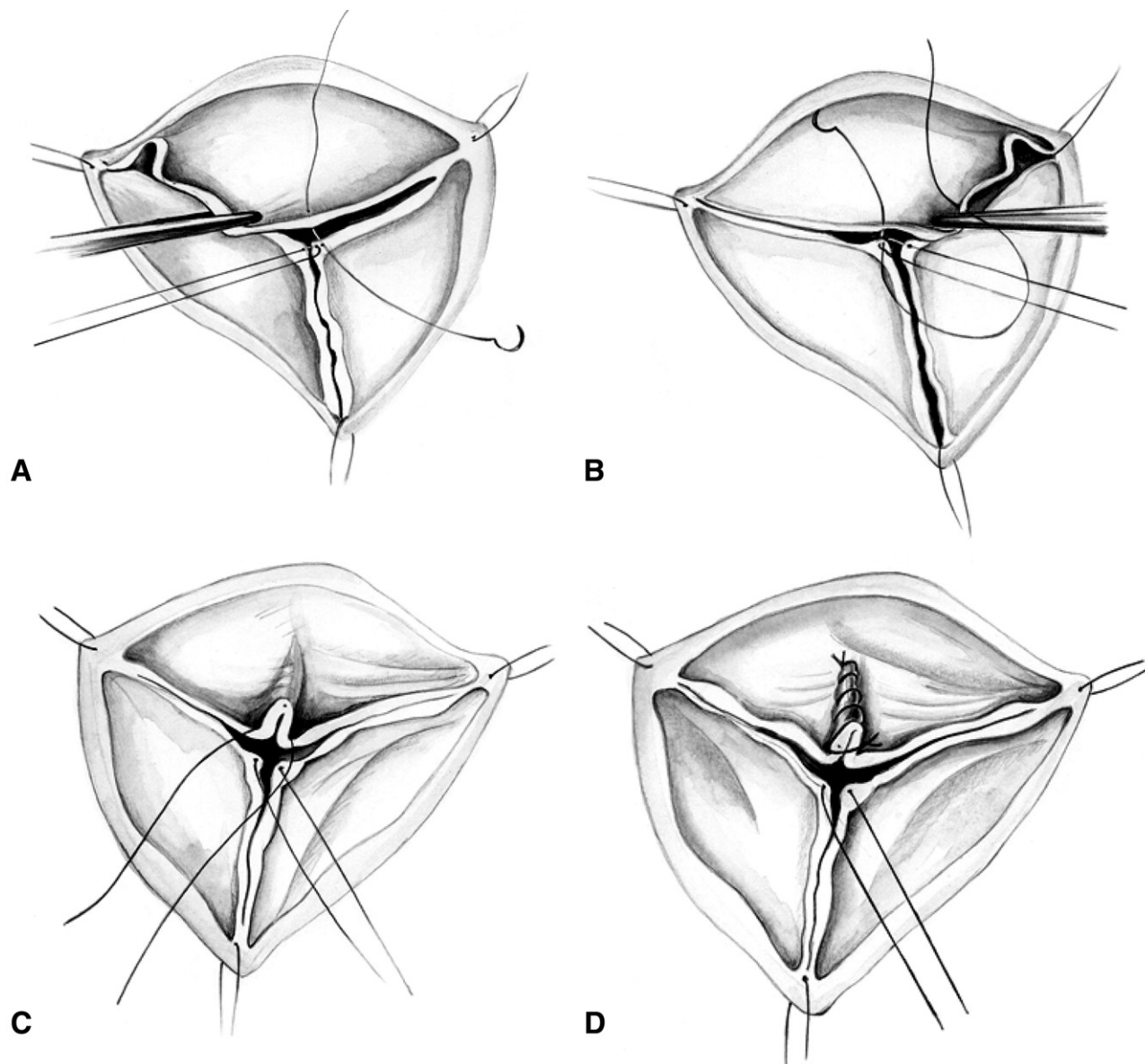


Figure 6 The technique for central free margin plication has been previously described.³ A 7-0 polypropylene suture is passed through the center of the two nonprolapsing reference cusps and gentle axial traction is applied. The prolapsing cusp is gently pulled parallel to the reference cusp and a 6-0 polypropylene suture is passed through the prolapsing cusp, from the aortic to ventricular side, at the point at which it meets the center of the reference cusp (A). Next, the direction of traction on the prolapsing cusp is reversed and the same suture is passed from the ventricular to the aortic side of the cusp where it meets the middle of the reference cusp (B). The length of cusp free margin between the two ends of this 6-0 suture represents the quantity of excess free margin, which is then plicated by tying this suture leaving the excess tissue on the aortic side (C).

The plication is extended by about 5 to 10 mm onto the body of the aortic cusp by adding interrupted or running locked 6-0 polypropylene sutures (D). If there is significant excessive tissue, it can be shaved off using a scalpel or scissors, keeping sufficient tissue to bring the edges together.

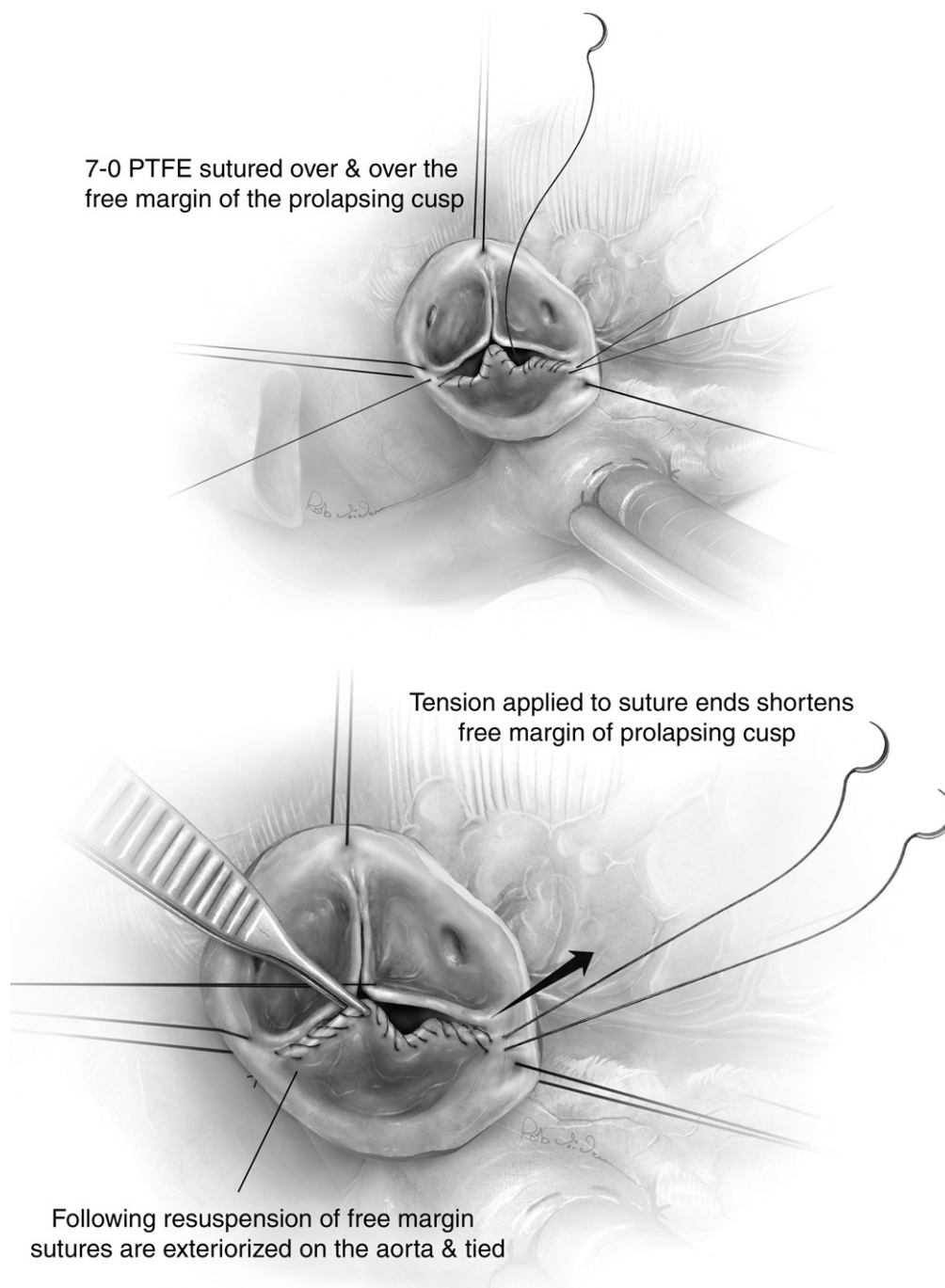


Figure 7 Excess length of the cusp free margin may also be corrected using resuspension with polytetrafluoroethylene (PTFE) suture. A 7-0 polypropylene suture is first passed through the center (nodule of Arantis) of the two nonprolapsing cusps, which serves as a reference. A 7-0 PTFE suture is passed twice at the top of the commissure. Next, one arm of the suture is passed over and over the length of the free margin in a running fashion. The suture is locked at the other commissure. A second 7-0 PTFE is then passed in the same fashion along the cusp free margin. The length of the free margin is reduced by applying gentle traction on each branch of the PTFE sutures and applying opposite resistance with a forceps at the middle of the free margin. This maneuver is used to plicate and shorten the free margin until it reaches the same length as the adjacent reference cusp free margin. The same maneuver is applied for the second half of the free margin. This two-step technique for free margin resuspension allows symmetric and homogenous shortening. When the appropriate amount of free margin shortening is achieved, the two suture ends at each commissure are tied.

This technique may be used in isolation or in combination with other cusp repair techniques and is particularly useful in the setting of a fragile free margin with multiple fenestrations or to homogenize the free margin when a pericardial patch is used for cusp augmentation. PTFE = polytetrafluoroethylene.

Cusp Repair: Bicuspid Aortic Valves

Cusp Anatomy in Bicuspid Aortic Valves

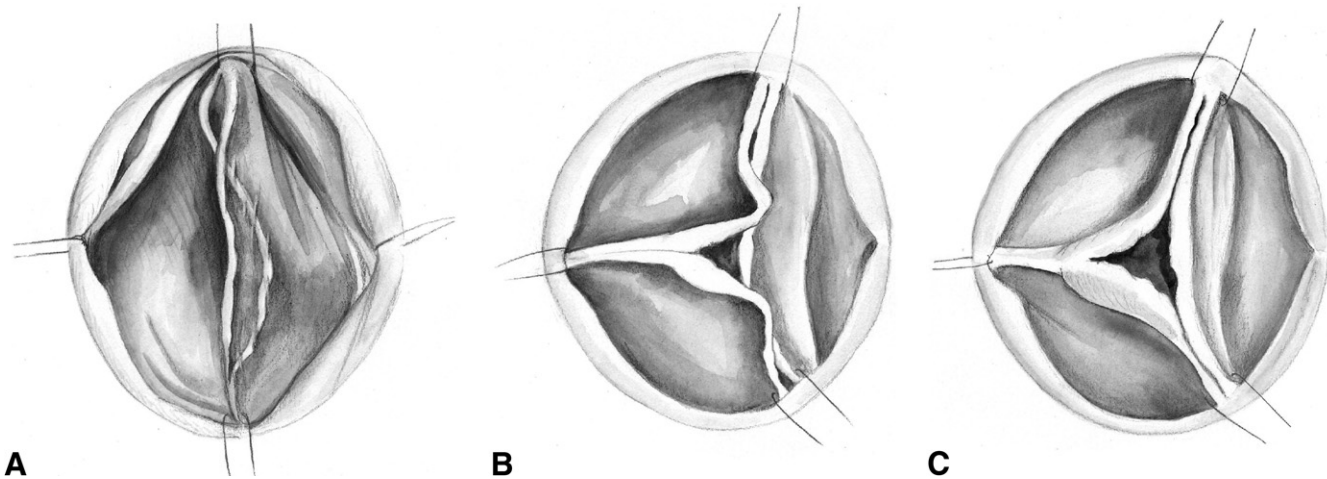


Figure 8 Cusp anatomy in bicuspid aortic valves. (A) Type 0 valve. (B) Type 1 valve with prolapsing conjoint cusp. (C) Type 1 valve with restrictive raphé.

Bicuspid aortic valve disease affects not only the valve cusps but also the functional aortic annulus. Bicuspid AV may be divided into two general types. Type 0 bicuspid AVs do not contain a median raphé and have two symmetric aortic sinuses, two commissures, and a symmetric base of leaflet implantation of the two cusps. This configuration is present in a minority of cases. The mechanism of AI in this setting is usually cusp prolapse of one or both cusps due to the presence of excess cusp tissue.

Type 1 bicuspid AVs, which are significantly more prevalent, have a median raphé on the conjoint cusp and an asymmetric distribution of the aortic sinuses with a large aortic sinus accompanying a large nonconjoint cusp and two smaller cusps fused together with a median raphé. The raphé

often attaches to the cusp base in the form of a “pseudocommissure,” which has a height lower than that of the true commissures. The raphé may be restrictive, fibrotic, calcified, or prolapsing. Furthermore, the base of leaflet implantation is typically larger (ie, occupying a greater proportion of valve circumference) and higher on the conjoint cusp compared with the nonconjoint cusp. The mechanisms of AI in type 1 valves can be due to a rigid and restrictive raphé associated with small fused cusps resulting in a triangular coaptation defect. Alternatively, the raphé may be short and nonrestrictive with well-developed cusps and associated prolapse of the conjoint cusp. Bicuspid valve anatomy can be anywhere along a spectrum between type 0 and type 1.

Type 0 Valve

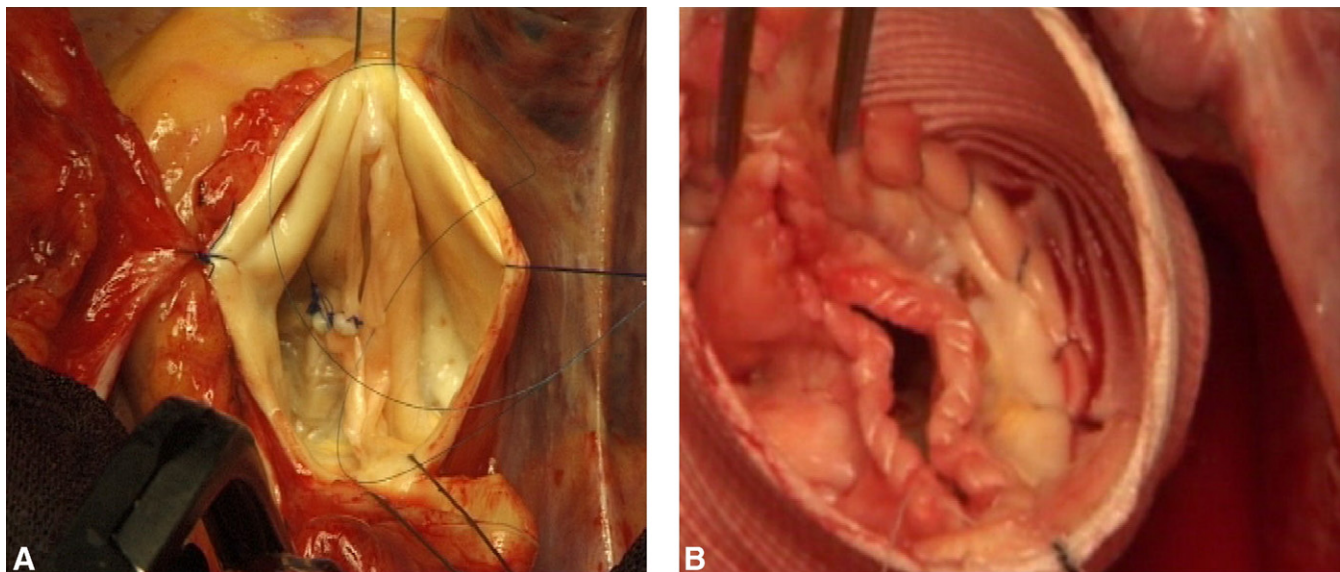


Figure 9 In type 0 valves, the degree of prolapse is assessed by comparing the prolapsing cusp to the nonprolapsing cusp, similar to trileaflet valves (Figs. 6 and 7). In the case where both cusps are prolapsing, the goal is to restore the height of coaptation to the midpoint of the sinuses of Valsalva. This may be performed using (A) free margin plication, (B) free margin resuspension with 7-0 PTFE suture, or both as previously described for trileaflet valves. Thickened, fibrotic areas of the leaflet (typically central aspect of the free margin) are shaved and localized decalcification is performed if calcium is present. (Color version of figure is available online at <http://www.optechtc.com>.)

Type 1 Valve: Raphé Shaving and Preservation

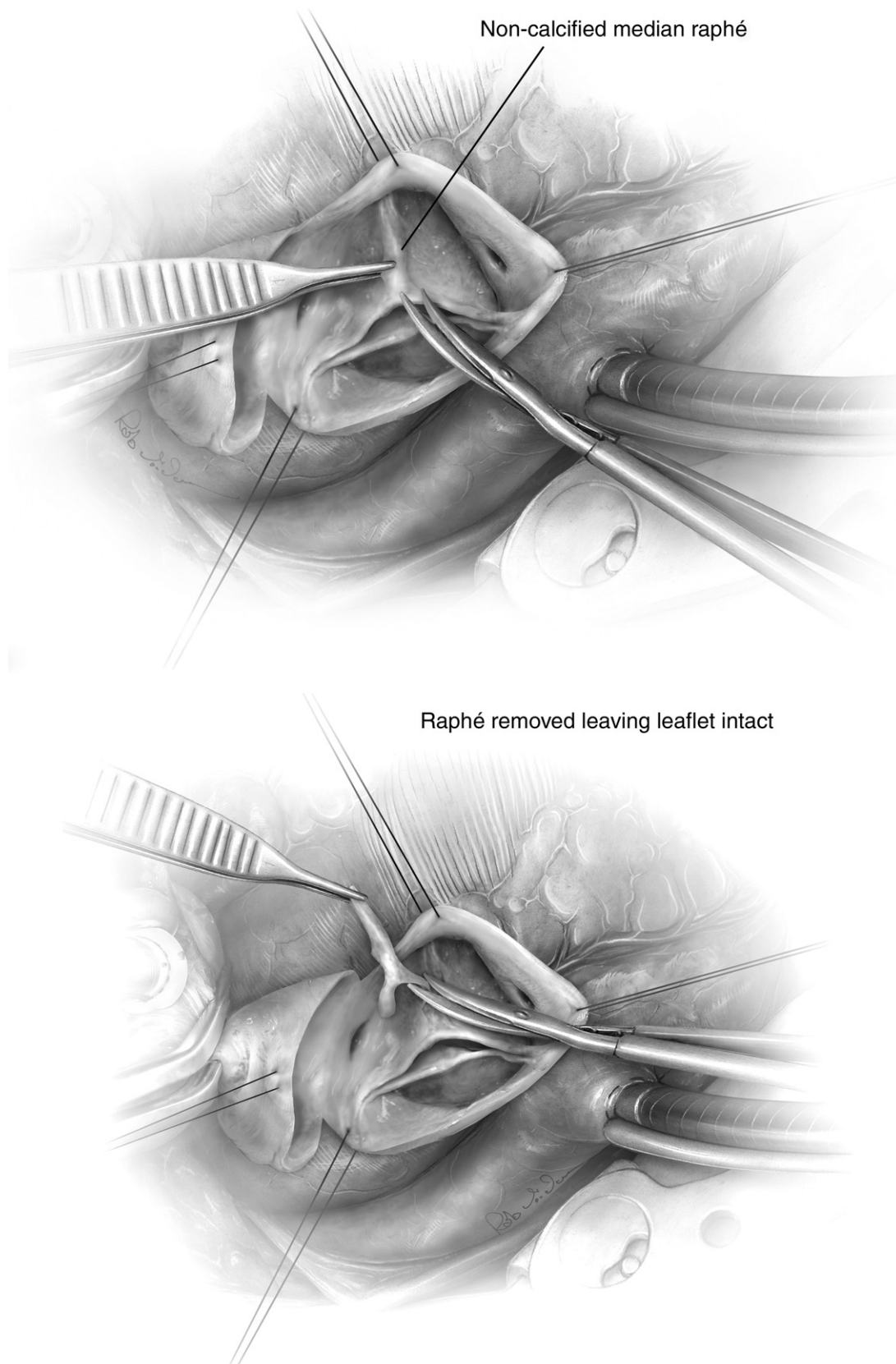


Figure 10 In type 1 valves, the median raphé was addressed first. If the raphé was relatively mobile and only mildly thickened and fibrosed, it was preserved and shaved using a combination of a scalpel and scissors.

Type 1 Valve: Management of a Restrictive or Calcified Raphé

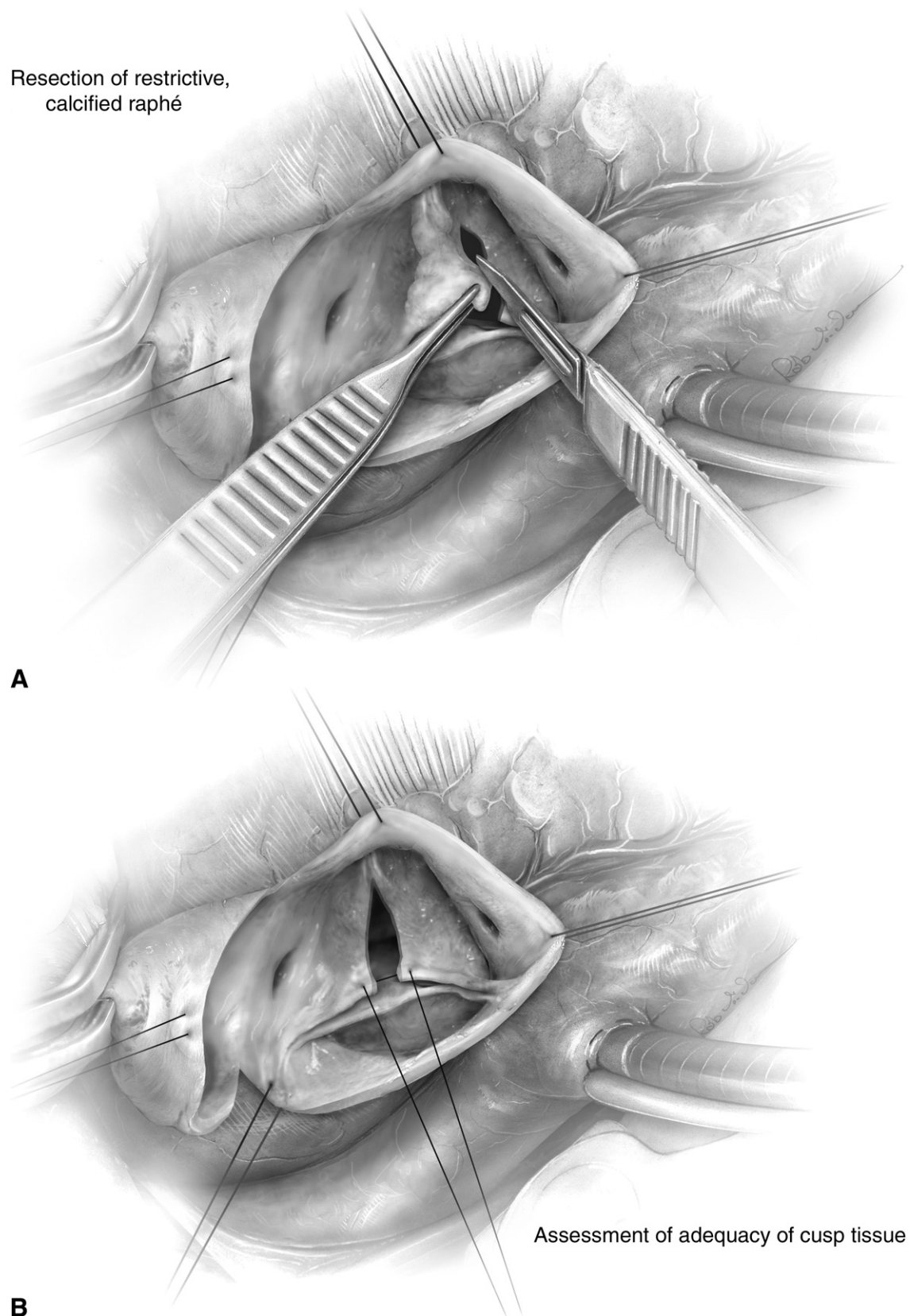


Figure 11 (A) When a severely restrictive or calcified raphé is present, a parsimonious triangular resection of this tissue is performed. (B) Next, the quantity of remaining cusp tissue is assessed by putting the two arms of a 6-0 polypropylene suture on the free margin of the conjoint cusp, on either side of the resected raphé. At this point, lack of cusp restriction and good valve opening are signs of the presence of adequate cusp tissue.

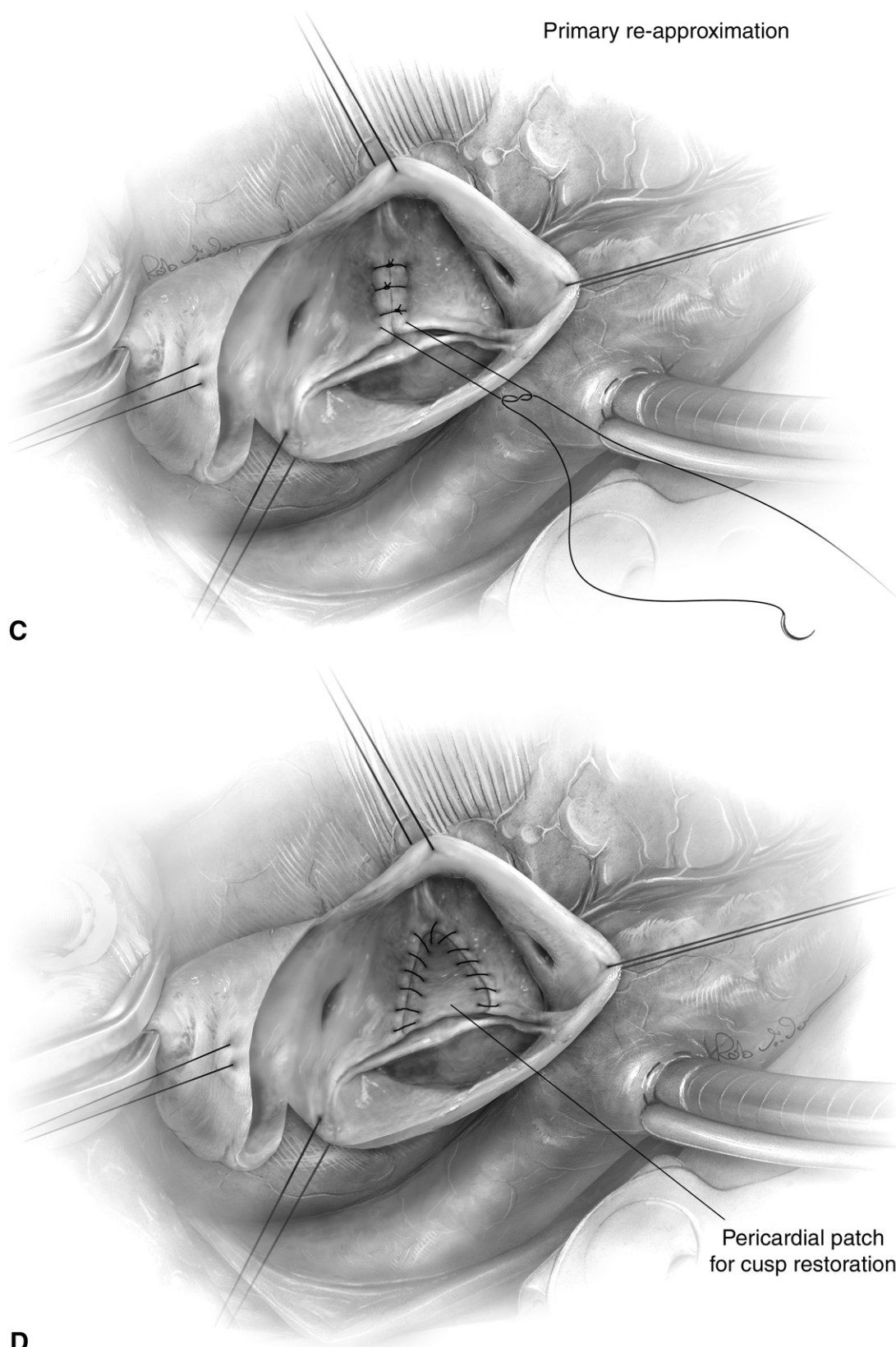


Figure 11 (Continued) (C) The leaflet edges are reapproximated primarily when adequate cusp tissue is present using running locked or interrupted 6-0 polypropylene sutures. (D) In the absence of adequate tissue, a triangular autologous treated or bovine pericardial patch is used for cusp restoration.

Next, the free margins of both cusps are compared for the presence of any prolapse, which is corrected using free margin plication or resuspension with PTFE.

Conclusions

Identification and classification of valve pathology is a cornerstone for the successful application of repair techniques to the aortic valve. Like the mitral valve, repair of the aortic valve requires the correction of cusp disease as well as reduction and/or stabilization of the aortic annulus. The overall aim of the repair procedure is to restore a normal surface, length, and height of coaptation, which is associated with improved long-term outcome.

The experience with aortic valve-sparing operations has paved the way for the development of techniques for aortic valve repair for aortic insufficiency. The current limitations of prosthetic valves, particularly in younger patients, make aortic valve repair an attractive alternative for the treatment of aortic insufficiency. These repair procedures have been shown to have excellent survival, acceptable risk of reoperation and recurrent AI at mid-term follow-up, and a low incidence of valve-related complications. Improvements in pa-

tient selection and surgical techniques will undoubtedly improve outcomes following aortic valve repair.

Supplementary Data

Supplementary data associated with this article can be found, in the online version, at [doi:10.1053/j.optechstcvs.2009.11.002](https://doi.org/10.1053/j.optechstcvs.2009.11.002).

References

1. Boodhwani M, de Kerchove L, El Khoury G: Aortic root replacement using the reimplantation technique: Tips and tricks. *Interact Cardiovasc Thorac Surg* 8:584-586, 2009
2. Boodhwani M, de Kerchove L, Glineur D, et al: Repair-oriented classification of aortic insufficiency: Impact on surgical techniques and clinical outcomes. *J Thorac Cardiovasc Surg* 137:286-294, 2009
3. Boodhwani M, de Kerchove L, Glineur D, et al: A simple method for the quantification and correction of aortic cusp prolapse by means of free margin plication. *J Thorac Cardiovasc Surg* 2009 Jun 25 (Epub ahead of print)