



The history of erectile dysfunction management

U Jonas^{1*}

¹Department of Urology, Hannover Medical School, Hannover, Germany

This article describes the evolution or revolution in the management of erectile dysfunction over the centuries. In recent history there has been a rapid movement away from a predominant role for the specialist towards the primary care physician. The physician is increasingly faced with the need to individualise therapy to meet patient expectations. *International Journal of Impotence Research* (2001) 13, Suppl 3, S3–S7.

Keywords: erectile dysfunction; history of medicine; penile surgery

Introduction

Erectile dysfunction (ED) is a significant problem, with over 150 million men in the US and 18–30 million in Germany affected. Although the disease is considered a benign disorder, it may have a dramatic impact on the quality of life of many men as well as their sexual partners. ED often results in anxiety, depression and lack of self-esteem and self-confidence, which in themselves can perpetuate the disorder.^{1,2}

Early history

An important figure in the history of ED is Regnier de Graaf, who, in 1668 discovered that the injection of saline into the penile blood vessels of cadavers could induce an erection.³ Francois de la Peyronie is known for his original description of Peyronie's disease in 1743, with the assumption at the time that he was himself a sufferer of the disease. In 1863, Eckhard published the first studies of an electrically induced penile erection in a dog (Figure 1).⁴

The French neurologist Charles Edouard Brown-Séquard put forward the theoretical links between hormone production and the ageing process. As early as 1869, he considered injecting semen into the blood of older men in order to increase mental and physical performance. Indeed, the first animal experiments on this theme were performed in 1875. At the age of 72, he experimented on himself by subcutaneously injecting animal testicular extract.⁵

During the course of 10 injections he reported an increase in physical and mental powers as well as an improved 'jet of urine' and the 'power of defaecation'. The pre-therapeutic state was resumed 4 weeks after treatment discontinuation. It is assumed that what Brown-Séquard experienced was indeed a placebo effect due to the low level of androgen he injected. Nevertheless, such experiments introduced the idea of androgen therapy to modern medicine.

Rejuvenation was clearly an important issue in ageing males. Another notable advocate of this procedure was the Russian, Serge Voronoff. Working in Paris, he was one of the first to transplant testicular tissue from a monkey into a human reproductive gland in 1920. In order to have the best long-term results, he only transplanted segments of the donor testis. He reported that hormonal secretion lasted for 1 to 2 y and then slowly decreased due to increasing fibrosis of the grafted tissue.⁶

Other historical landmarks for ED therapy include the reporting in 1908 by Frank Lydston of over 100 dorsal vein ligation procedures, with the realisation of the role of the vascular system in penile erection.⁷ The first vacuum device was patented by Otto Lederer in 1913, but this had previously been proposed by Muschenbrack, who described air pumps in 1694. Interestingly, the patented device is very similar to modern day equipment. Nicolai Bogoras reported the first total phalloplasty in 1936 following amputation of the penis.⁸

Penile implants

In 1936, Bogoras carried out one of the first penile implants using rib cartilage and bone in order to

*Correspondence: U Jonas, Department of Urology, Hannover Medical School, Carl Neubergstraße 1, D-30625, Hannover, Germany.
E-mail: Jonas.Udo@MH-Hannover.de

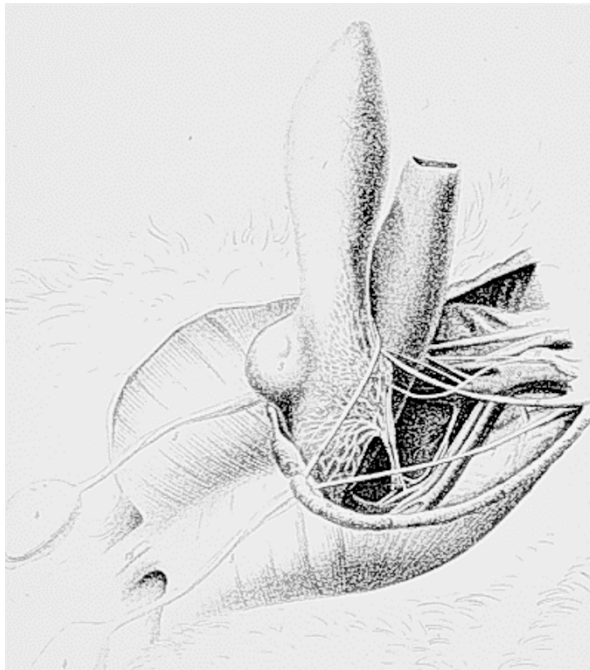


Figure 1 Anatomy of the canine penis showing the neural supply.⁴

restore penile rigidity. However, the implant was reabsorbed after several months and the effect abolished. The first alloplastic implants were described in 1952 using acrylic prostheses.^{9,10} These devices were originally positioned between the corpora cavernosa. However, they were less successful than polyethylene prostheses, which were implanted inside the tunica albuginea. By 1966, Beheri had already reported on 700 penile implants using two polyethylene rods, each placed inside one of the corpora cavernosa.^{11,12} After having finally found the appropriate material (silicone rubber) and the exact implantation site (inside the tunica albuginea), prosthetic surgery for the treatment of ED became more and more popular, despite the fact that by creating space inside the corporal body, corporal tissue and residual function had to be destroyed.

In 1973, Scott and co-workers described a completely new concept using inflatable silicone cylinders. These could be filled voluntarily from fluid stored in a reservoir positioned behind the rectus muscle using a pump implanted in the scrotum (Figure 2).¹³ In 1975, Small and Carrion designed a prosthesis that was much easier to implant and had less complications, but which had the disadvantage of a more-or-less permanent erection due to the rigid rods positioned inside the corpora cavernosa.¹⁴

Penile implants currently give the best results in terms of achieving an erection, but the disadvantages are invasiveness, complications and mechan-

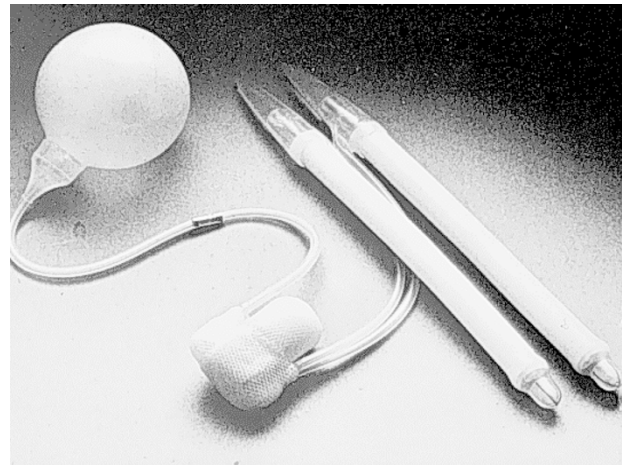


Figure 2 AMS inflatable penile prosthesis.²

ical failure. The First International Consultation on Erectile Dysfunction in July 1999¹ states that penile implants are the last resort for treatment despite the fact that with this type of surgery the best outcome might be expected. It is evident that only 10% of patients with ED will receive an alloplastic implant.

Malleable implants

The malleable device designed by Small and Carrion consisted of a pair of silicone rod prostheses, which were originally implanted through a midline perineal incision. It was available in different lengths and diameters, emphasizing the inability to make a proper length determination prior to surgery.¹⁴ The later introduction of individual device trimming at the tails of the implants allowed a reduction in the number of differently sized devices.

The rigid characteristics of this device meant that the patient had a more or less permanent erection. Subrini¹⁵ and Finney¹⁶ overcame this problem through the use of softer silicone in the midpart of the device. Finney's device—the 'flexirod hinged silicone penile implant'—allowed the penis to hang down normally and to be brought up erect for the purposes of sexual intercourse.¹⁶

In 1978, the author published a report on a silicone silver penile prosthesis (Figure 3), which was characterised by silver wires embedded inside the silicone rubber to stabilise the penis in different positions. With this technique, the penis could be brought into the 'erected' position by an easy manual manoeuvre without the potential risk of complications associated with the more complex systems.¹⁷ Current success rates with malleable implants are around 92% and there appears to be fewer complications than with inflatable devices.

Inflatable implants

Currently, three inflatable implants are available: one-, two- or three-component. Inflatable devices are used more frequently than malleable devices due to their improved cosmetic appearance and functionality. Overall success rate is around 86% (includes repeat operations), but complications include infection (1–10%) and mechanical malfunction (<5%).¹⁸ The currently available penile implants are shown in Figure 4. It must be recognised that, to




Figure 3 Silicone silver penile prosthesis.¹⁷

date, the vast majority of patients prefer the inflatable devices due to their more elegant handling and better cosmetic appearance. Time will tell, however, if this will be true in the future due to the high costs of these implants.

Vacuum devices

The vacuum pump in current use is a development of Lederer's patented device. A variety of pumps are available, but the most commonly used one is the EricAid pump from Osbon Medical Systems (Augusta, GA, USA) (Figure 5). These devices work by exerting a negative pressure on the penis, which results in an increase in corporeal blood flow and erection.¹⁹ A constriction ring placed around the base of the penis prolongs the erection by decreasing corporeal drainage. The time taken to achieve an erection varies, but is generally around 2–2.5 min. The constriction band should not be left in place for more than 30 min, but the procedure can be repeated for prolonged intercourse.

Disadvantages to the technique are that as the penis only becomes rigid distal to the constriction band, there is a lack of fixation compared with a normal erection, ie the penis may pivot at the base to produce a fulcrum effect. Also, with the decreased blood flow into the penis, the penis may become slightly cool and bluish in colour due to cyanosis. In addition, petechiae of the penis may occur and the penis can have a slightly numb feeling. From 1996 to

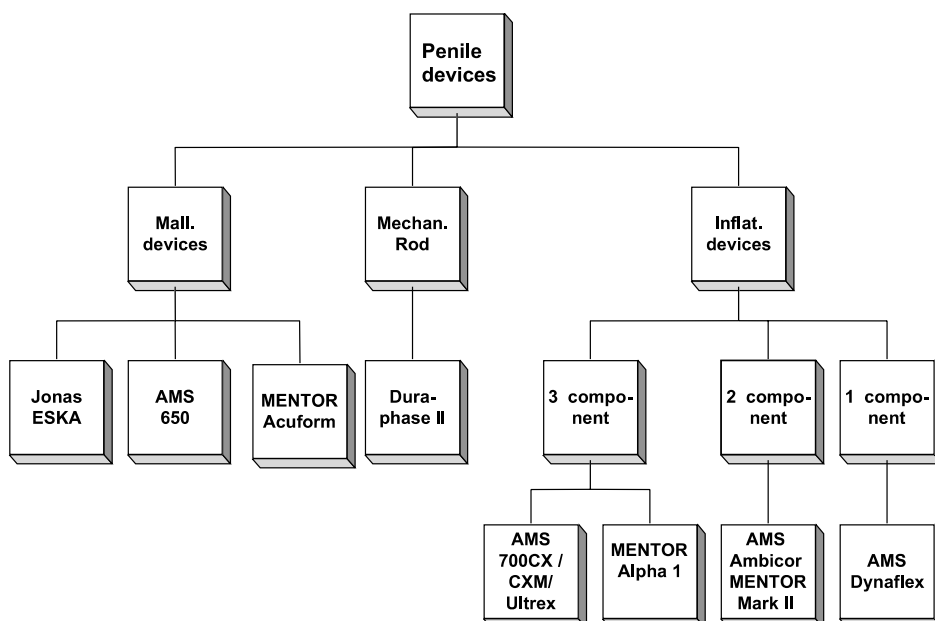


Figure 4 Different types of penile implants.

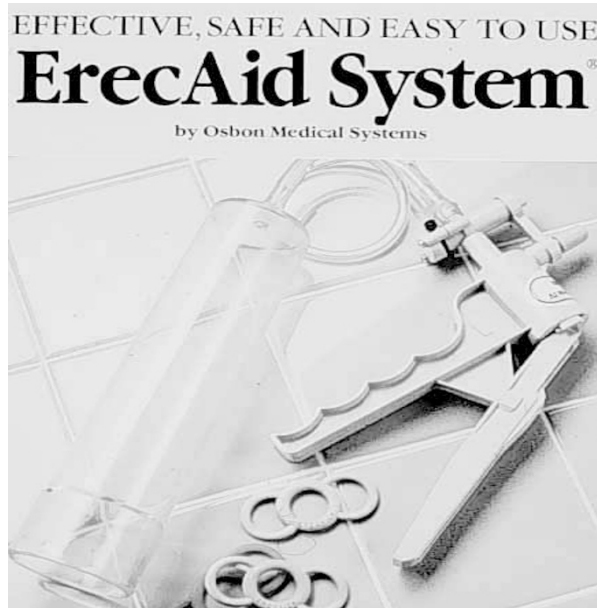


Figure 5 The vacuum device.

1998, use of the vacuum device declined from 8 to 4% in Germany, from 3 to 0.1% in Italy and from 13 to 7% in the UK, suggesting a waning enthusiasm in both physicians and patients.

The vacuum device may be used in most patients with ED, with success rates of the order of 74%. However, due to complications it should not be used in patients with the following conditions:

- Severe penile scarring of the corpora cavernosa: penile engorgement may not be satisfactory.
- Severe Peyronie's curvature: restricted movement within the cylinder.
- Severe phimosis: may require prior circumcision.

Vascular surgery

Arterial revascularisation

There are several surgical techniques for restoring arterial circulation in the penis. The Michal procedure involves an anastomosis between the inferior epigastric artery and the proximal part of the dorsal penile artery. In the DDVA procedure, the epigastric artery is anastomosed end-to-side to the proximal part of the deep dorsal vein. The Hauri technique involves an anastomosis between the inferior epigastric artery, one of the dorsal penile arteries and the deep dorsal vein. The results of such techniques are controversial, ranging from 38 to 79%, and success does decline with time. In the widely used VIRAG V procedure, the inferior epigastric artery is

anastomosed end-to-side with the deep dorsal vein in combination with the ligation of the proximal and distal vein and the emissary collaterals and the formation of a fistula between the dorsal vein and the corpus cavernosum.

Serious complications include glans penis hyperaemia, spongy necrosis and glans hypesthesia. The surgery is lengthy, lasting on average 2.5 h and the indication is more than questionable.²⁰

Venous leakage

Careful patient selection is important in venous leakage surgery; excluded are those with arterial or nervous pathology. Surgery involves ligation of the two main drainage routes in the penis: the deep dorsal vein and the cavernosal veins. Venous ligation restores spontaneous erections in less than 30% of patients and is probably a reflection of the poor understanding of the causes of veno-occlusive dysfunction. Long-term improvement is inconsistent.²¹

Local therapies

Intracavernosal therapy

Intracavernosal therapy is indicated following failure of oral drug therapy. Injection of alprostadil, a naturally occurring prostaglandin E₁ (PGE₁), into the corpora cavernosa leads to relaxation of the penile smooth muscle and induction of an erection. It is effective in the majority of patients (75–79%) and patient–partner satisfaction is high (73–86%). Onset of action is rapid.²²

One local side effect is pain, which is more likely in patients with anatomic deformities of the penis, such as angulation, phimosis, cavernosal fibrosis, Peyronie's disease or plaques. Alprostadil may be used in combination with phentolamine to allow a reduction in dose and a decrease in dose-related pain. In common with other intracavernosal therapies, corporal fibrosis may occur at the injection site with prolonged use. Priapism is also possible. Intracavernosal alprostadil is contraindicated in patients with sickle cell anaemia and other conditions that predispose to priapism.

Intraurethral agents

Alprostadil can also be administered intraurethally via a novel system termed MUSE (medicated urethral system for erection).²³ Alprostadil is ra-

pidly absorbed across the urethral mucosa to give an average onset of action of 20 min. Clinical efficacy has not translated in general use and results are disappointing. The main side effects are pain, which is the main reason for treatment discontinuation, and systemic hypertension.

Oral therapy

The advantages of oral drugs are ease of administration, patient acceptance and relative efficacy. Disadvantages include specific contraindications, cost, and possible limited long-term results. Agents can be centrally acting, for example apomorphine, or peripherally acting, as with the phosphodiesterase 5 (PDE5) inhibitor sildenafil.²⁴ The efficacy of sildenafil in the treatment of ED has been demonstrated in patients with diabetes, hypertension and depression.^{25–27} Although more than 1500 deaths have been reported in patients on sildenafil, myocardial infarction rates and death rates are reported to be the same with sildenafil and placebo.²⁸ Histomorphological studies did not detect any PDE5 in ventricle tissue, but significant levels were found in the atrium.²⁹ A review of oral therapy for ED was recently published in the *World Journal of Urology*.³⁰

Conclusion

The management of ED has evolved over the past decades, from implantation of the first penile devices without any knowledge of the pathophysiology and mechanism of erection, through injection and oral therapy, which have allowed elucidation of the complex pathways involved. The best therapy will certainly be the least invasive one, which enables physiological sexual behaviour that is 'age adapted'. Oral treatment meets this goal provided that the medication is well tolerated, safe and effective. Although the availability of oral agents for the treatment of ED has changed the lives of millions, there is room for improvement. Time will tell the advantages a drug such as apomorphine SL (Uprima®) that has a rapid onset of action may have or which restores sexual activity to a more natural setting.

References

- 1 Jardin A *et al.* The First International Consultation on Erectile Dysfunction, Paris 1999. Health Publications Ltd: Jersey, 2000.
- 2 Feldman HA *et al.* Impotence and its medical and psychological correlates: results from the Massachusetts Male Ageing Study. *J Urol* 1994; **151**: 54–61.
- 3 Jocelyn HD, Setchell BP. Regnier de Graaf on the human reproductive organs: an annotated translation of *Tractatus de virorum organis generationi inservientibus* (1668). *J Reprod Fertil* 1972; **17**: 97–99.
- 4 Eckhard C. Untersuchungen über die Erektion des Penis beim Hunde. In: Eckhard C (ed). *Beiträge zur Anatomie und Physiologie*. Giessen: 3. Band, 1863, pp 270–285.
- 5 Brown-Sequard C. Des effets produits chez l'homme par des injections sous-cutanées d'un liquide retiré des testicules frais de cobaye et de chien. *Compt Rend Soc Biol* 1889; **41**: 415–416.
- 6 Schultheiss D, Denil J, Jonas U. Rejuvenation in the early 20th century. *Andrologia* 1997; **29**: 351–355.
- 7 Lydston GF. The surgical treatment of impotency: further observations on the resection of the vena dorsalis penis in appropriate cases of impotence in the male, with a record of experiences. *Am J Clin Med* 1908; **15**: 1571–1573.
- 8 Bogoras NA. Über die volle plastische Wiederherstellung eines zum Koitus fähigen Penis (Penioplastica totalis). *Zentralbl Chir* 1936; **63**: 1271.
- 9 Gee WF. A history of surgical treatment of impotence. *Urology* 1975; **5**: 401–405.
- 10 Loeffler RA, Sayegh ES. Perforated acrylic implants in management of organic impotence. *J Urol* 1960; **84**: 559–562.
- 11 Beheri GE. The problem of impotence solved by a new surgical operation. *Ann J Surg* 1960; **1**: 50.
- 12 Beheri GE. Surgical treatment of impotence. *Plast Reconst Surg* 1966; **38**: 92–97.
- 13 Scott FB, Bradley WE, Timm GW. Management of erectile impotence: use of implantable inflatable prosthesis. *Urology* 1973; **2**: 80–82.
- 14 Small MP, Carrion HM, Gordon JA. Small-Carrion penile prosthesis: new implant for management of impotence. *Urology* 1975; **5**: 479–486.
- 15 Subrini L, Couvelaire R. Le traitement chirurgical de l'impuissance virile par intubation prothétique intracaverneuse. *J Urol Nephrol* 1974; **80**: 269–276.
- 16 Finney RP. New hinged silicone implant. *J Urol* 1977; **118**: 585–590.
- 17 Jonas U, Jacobi GH. Silver-silicone penile prosthesis. *J Urol* 1980; **123**: 865–867.
- 18 Daitch JA *et al.* Long-term mechanical reliability of AMS 700 series inflatable penile prosthesis: comparison of CX/CXM and Ultrex cylinders. *J Urol* 1997; **158**: 1400–1402.
- 19 Oakley N, Moore KTH. Vacuum devices in erectile dysfunction: indications and efficacy. *Br J Urol* 1998; **82**: 673–681.
- 20 Manning M *et al.* Long-term follow up and selection criteria for penile revascularization in erectile failure. *J Urol* 1998; **160**: 1680–1684.
- 21 Schultheiss D *et al.* Long-term results following dorsal penile vein ligation in 126 patients with veno-occlusive dysfunction. *Int J Impot Res* 1997; **9**: 205–209.
- 22 Truss MC, Becker AJ, Schultheiss D, Jonas U. Intracavernous pharmacotherapy. *World J Urol* 1997; **15**: 71–77.
- 23 Padma-Nathan H *et al.* Treatment of men with erectile dysfunction with transurethral alprostadil. *New Engl J Med* 1997; **336**: 1–7.
- 24 Heaton JPW, Adams MA, Morales A. A therapeutic taxonomy of treatments for erectile dysfunction: an evolutionary imperative. *Int J Impot Res* 1996; **9**: 115–121.
- 25 Goldstein I *et al.* Oral sildenafil in the treatment of erectile dysfunction. *New Engl J Med* 1998; **338**: 1397–1404.
- 26 Morales A *et al.* Clinical safety of oral sildenafil citrate (VIAGRA) in the treatment of erectile dysfunction. *Int J Impot Res* 1998; **10**: 69–74.
- 27 Langtry HD, Markham A. Sildenafil: a review of its use in erectile dysfunction. *Drugs* 1999; **57**: 967–989.
- 28 Zusman RM. Cardiovascular data on sildenafil citrate. *Am J Cardiol* 1999; **83**: 1–44.
- 29 Kütke A *et al.* Gene expression of the phosphodiesterase 3A and 5A in human corpus cavernosum penis. *Eur Urol* 2000; **38**: 108–114.
- 30 Stief CG, Krane RJ. Oral treatment for ED. *World J Urol* 2001; **19**: 1–73.